

OCULAR SIDE EFFECTS OF SYSTEMIC DRUGS

Pragati Garg, Swati Yadav

Department of Ophthalmology

Era's Lucknow Medical College & Hospital, Sarfarazganj Lucknow, U.P., India-226003

Received on : 06-03-2019

Accepted on : 28-06-2019

ABSTRACT

Systemic drugs are frequently administered in persons of all age group ranging from children to the elderly for various disorders. There has been increased reporting of ocular side effects of various systemic drugs in the past two decades. Some offenders well known are α -2-adrenergic agonists, quinine derivatives, β -adrenergic antagonists and antituberculosis drugs. Newer systemic drugs causing ocular side effects are being reported in available literature. Knowledge regarding these is expected to aid clinicians in identifying these side effects and the offending drug, thereby, prescribing the appropriate treatment for the condition the patient maybe suffering from without any ocular disturbances.

KEYWORDS: Ocular side effects, Systemic drugs.

Introduction

Many common systemic medications can affect ocular tissues and visual function to varying degrees. When a systemic medication is taken to treat another part of the body, the eyes frequently are affected. Systemic medications can have adverse effects on the eyes that range from dry eye syndrome, keratitis and cataract to blinding complications of toxic retinopathy and optic neuropathy (1). Some of these side-effects, though undesirable, have to be accepted as unavoidable. The discovery of serious ocular defects arising in association with the long-term use in high dosage of certain drugs has indicated the need for all prescribers to be aware of the risks involved. Particularly this is important since some of the toxic effects have seriously impaired vision and proved to be irreversible.

When patients present with ocular symptoms that have no apparent cause, it is important to consider whether the condition could be caused by a systemic medication they are taking. Patients often neglect to mention the maintenance drugs that they take every day, so ophthalmologists may need to ask specifically about these types of medication. One of the most important aspect is obtaining a thorough medical history which includes specific medication dosage and duration of treatment (2). Patient safety is essential during treatment for a particular disorder.

There is much awareness of systemic effects of ocular eye drops due to absorption through nasal mucosa. It is much needed to be aware of the ocular side effects of systemic drugs also for better patient compliance and satisfaction.

Address for correspondence

Dr. Pragati Garg

Department of Ophthalmology
Era's Lucknow Medical College &
Hospital, Lucknow-226003
Email: drpragati89@gmail.com
Contact no: +91-9415396506

This article will briefly cover how systemic drugs can affect the various ocular structures.

Factors Affecting The Production Of Ocular Side Effects By A Drug

A) Drug related factors

(1) **The nature of the drug:** Absorption of drug in body and its pharmacological effects on the body's metabolism is effected by nature of drug. The ease with which a drug passes into the general circulation and into the eye determines the ability of systemically administered drugs to affect the eye directly.

(2) **The amount of the drug consumed:** The daily consumption of high doses of drugs reaches toxic levels to effect the eye. In addition, prolonged consumption of drugs whose detoxification and excretion is low determines the effect on eyes.

(3) **The route of its administration:** Drugs are administered locally, orally or through parenteral route. Topical application of drugs, allows sufficient absorption to risk ocular side effects.

(4) **Pathological condition of patient:** Liver and renal diseases frequently affect the detoxication and excretion of drugs, allowing them to accumulate to toxic levels. In some instances, it is difficult to determine whether an ocular defect has arisen as a result of involvement with the general disease or as a toxic manifestation of a drug used in therapy.

(5) **Effect of drug combination:** Certain drugs consumed in combination with other substances have potentiated toxic effects.

(6) Previous exposure to the drug: The ability of non-protein drugs to act as haptens sensitize the patient and are thus, responsible for iatrogenic disease, particularly where drugs are applied topically over long periods.

(7) Drug metabolism: The body's ability to metabolize a drug directly correlates with toxicity. In patients with liver and kidney disease, there is a decreased rate of excretion, which allows drug molecules to accumulate to toxic levels (3). Also, toxic metabolites formed elsewhere like the liver, can reach the eye through systemic circulation or can be produced locally in ocular tissues.

B) Ocular factors

The eyes are generally affected when a systemic medication is taken to treat some other part of the body. Following systemic administration, the blood-aqueous barrier and blood-retinal barrier are the major barriers for anterior segment and posterior segment ocular drug delivery, respectively⁴. The choroid, sclera and ciliary body have thin, fenestrated walls for drug molecules to pass through. Small, lipid soluble molecules, which pass freely into the aqueous humor, can further diffuse into a circulation. The drug molecules can enter the eye and contact various ocular tissues, and eventually accumulate in ocular tissues or exit the eye. There are three major accumulation sites including the cornea, lens and vitreous. The duration of action of drug in the eye is prolonged if it is deposited, increasing chances for toxicity (4).

The cornea has a permeable endothelium, and the stromal glycosaminoglycans (GAGs) which can bind to drug molecules, leading to edema and decreased transparency. Drug molecules can also bind to lens proteins and photosensitize the lens to ultraviolet (UV) radiation. Lastly, drug molecules tend to accumulate in the vitreous due to the slow rate of fluid exchange in the lens, cornea, and trabecular meshwork (2).

List Of Ocular Side Effects Of Some Common Systemic Drugs

A) Antihypertensive drugs

1. Beta-blockers: Beta-blockers, used to treat hypertension, reduce tear lysozyme levels and immunoglobulin A (IgA) which leads to reduction in tear secretion, and patients complain of ocular irritation, dry eye symptoms, and contact lens intolerance (5).

Artificial tear supplementation and refitting the patient with soft contact lenses should be done as management. Beta blockers also decrease intraocular pressure (IOP) by blocking the beta-2 (β_2) receptors on

the non pigmented ciliary epithelium, which causes reduction in aqueous formation by the ciliary body (5). Topical β_2 blockers produce little additional IOP reduction with concomitant administration of a non-selective (β_1 and β_2) systemic beta-blocker. Some patients may be misdiagnosed as normal tension glaucoma because the IOP is artificially reduced, appearing within normal limits.

2. Diuretics

Hydrochlorothiazide (HCTZ) is a diuretic commonly used to treat congestive heart failure, and sometimes causes dry eye by changing the tear film. It reduces lysozyme levels and immunoglobulin A, and also causes a decrease in aqueous production and. The tear potassium is found decreased significantly in subjects taking hydrochlorothiazide (6). Myopic shift and band keratopathy have been reported, however, occurrence is not common (6). Exact mechanism producing acute myopia is not very clear even though it has been postulated to be due to ciliary body effusion, (7) peripheral uveal effusion (8) and ciliary spasm and lens swelling. Oral sulphonamides cause transient myopia as a result of forward displacement of the lens due to allergic ciliary body oedema and rotation (9-10).

3. Angiotensin Converting Enzyme (ACE) Inhibitors

These are commonly used as antihypertensive drugs which can cause decreased vision, photosensitivity, conjunctivitis, lid edema and discoloration and blepharitis. Enzyme activities of ACE have been reported further in production of aqueous humour, vitreous humour and tear fluid, also in retina, and ciliary body, which are inhibited by these drugs (11).

4. Antiarrhythmics

a) Amiodarone: It is used to treat various cardiac arrhythmias like atrial fibrillation and ventricular tachycardia, which causes certain ocular side effects. Studies have found the presence of amiodarone in all ocular tissues when systematically administered. Keratopathy is the most common ocular adverse effect of amiodarone found in almost all patients (70-100%) (12). It most commonly appears after 1-4 months of therapy. Involvement is bilateral but is often asymmetric. Toxicity increases with higher doses and longer therapy.

Amiodarone tends to cause whorl-like corneal deposits in as early as six days of treatment but more commonly in one to three months of treatment. The deposits appear whorl-like because epithelial cells migrate centripetally from limbus.

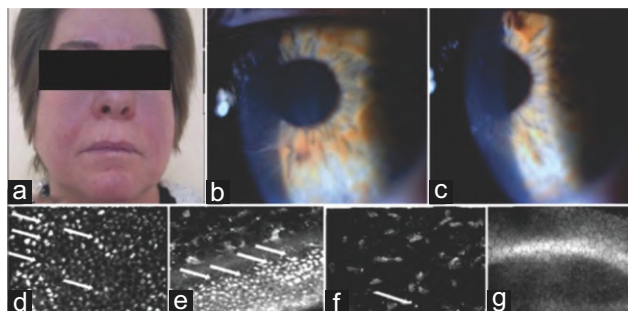


Fig 1: (a) Blue-grey Discoloration On The Nose And Central Cheeks. Amiodarone - Induced Corneal Opacities; (b) Horizontal Line In The Inferior Third Of The Cornea In The Right Eye, (c) Whorl-Like Pattern Of Powdery, White, Yellow Or Brown Corneal Deposits Of The Left Eye. In Vivo Confocal Microscopic Images Of Hyperreflective Intracellular Inclusions Of Amiodarone Keratopathy (d) In Epithelial Cells, (e) In Basal Epithelial Cells, (f) In Stroma, (g) No Deposits In The Endothelium (13).

Severity of keratopathy appears to significantly correlate with total drug dosage and duration of therapy. Patients taking higher doses >400mg/day demonstrate more advanced keratopathy depending on the duration of treatment. Keratopathy remains relatively stationary until the drug dosage is reduced. Keratopathy resolves within 3-20 months of discontinuation of the medication. corneal changes associated with amiodarone therapy are benign and special follow up of affected patients is not needed (12).

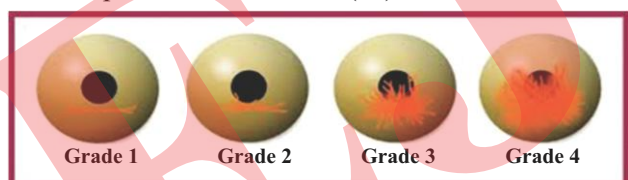


Fig 2: Grades of Amiodarone Keratopathy

Being photosensitizing agent, amiodarone can also causes anterior and posterior sub-capsular lens changes. It also has tendency of lipid storage in cornea and lens (2). There have been recent cases of optic neuropathy with vision loss as well as reports of Pseudotumor cerebri, however these were also observed to be reversible with the discontinuation of amiodarone therapy (14).

Reduction of IOP in glaucomatous and non-glaucomatous eyes is also reported (2).

a) Cardiac glycosides- Digitalis/digoxin

Digoxin has been known for a very long time to cause visual effects, photoreceptor color vision phenomena. It inhibits $\text{Na}^+\text{-K}^+\text{ATPase}$ in the ciliary epithelium (10). This enzyme is responsible for the active transport of

sodium, necessary for aqueous secretion. It inhibits the transport of Na^+ necessary for aqueous secretion and thus causes reduced aqueous secretion and IOP². Along with the ocular side effects, there are numerous systemic side effects associated with this drug precluding its use in glaucoma treatments (15). Other ocular side effects reported regularly with use of digoxin are blurred vision and peri-central scotomas (16).

b) Anti-anginal drugs

- **Nitroglycerin:** leads to decreased vision and coloured halos, variations in intraocular pressure, pseudotumor cerebri, Ocular side effects observed with other antianginal drug include photosensitivity, amblyopia, periorbital edema, lacrimation, subconjunctival and retinal hemorrhages (15).

c) Antihyperlipidemics

Patients with high cholesterol are often treated with anti-hyperlipidemic drugs. One of the earlier investigations of lovastatin showed high rate of lens opacities (14). Statins inhibit lens epithelial cell death. This supports the theory that oxidative damage to the lens epithelium may cause proteins to coagulate and form cataracts. Perhaps statins scavenge the free radicals that damage the lens with light and oxygen. Anti-hyperlipidemics lead to dry eye and cystoid macular edema (11). Symptoms of lid edema and blurred vision may also occur (2).

G) Hypoglycemic drugs

- Chlorpropamide is used less often with the advent of second generation sulphonylureas. However, certain ocular side effect are worthy of note. It can result in central or centrocaecal scotoma. This effect is acute and bilateral, but reduces if the drug is discontinued. Visual loss due to chlorpropamide-induced optic neuropathy was also reported (17)

- Sulphonylureas like glibenclamide and gliclazide have been used to treat diabetes (3). These have shown to inhibit the vasoconstriction of retinal and ciliary arteries induced by prostaglandins. This may have the result of increasing blood flow in the diabetic retina as an extra beneficial effect. On the other hand, the protective effect on retina is blocked by another sulphonylurea, tolbutamide (18). Some glycation end products (AGEs) promote the expression of vascular endothelial growth. Gliclazide has been shown to inhibit this process. This action can be attributed to the antioxidant properties of this drug (19). Gliclazide in particular has also been shown very recently (20) to inhibit retinal leukostasis. (Early leukocyte entrapment in the retinal microvasculature is regarded as one of the pathogenetic mechanisms of diabetic retinopathy.) Lightman (21) reported in

patients on glyburide, a second generation sulphonylurea, development of crystalline lens changes and refractive error shifts in the absence of variations in blood glucose level. This drug is a more potent osmotic agent than its predecessors.

3) Thiazolidinediones (TZDs) - The more recently introduced but yet widely prescribed agents, pioglitazone and rosiglitazone, have been demonstrated in animal models to inhibit the progression of retinal and choroidal neovascularization, both in diabetes mellitus and macular degeneration. This is achieved via inhibition of vascular endothelial growth factor/VEGF induced proliferation migration and tube formation of retinal endothelial cells (RECs) (22). Association of macular edema with use of a TZD has been reported in some case reports and review articles but the overall evidence either proving or disproving it is fair at best. However, most experts in the field believe that TZDs probably exacerbate macular edema and that with discontinuation of TZDs, macular edema may decrease or abate completely (23).

D) Hormones

1) **Levothyroxine:** Longterm use of Levothyroxine have been found to lead to visual hallucinations, eyelid hyperemia and pseudotumor cerebri (PTC), which disappear with discontinuation of the drug (3). Some patients have noticed visual hallucinations with this drug. Use of oral contraceptive is commonly known to cause dry eye and contact lens intolerance from reduced tear secretion (2).

2) **Hormone Replacement Therapy (HRT) with Estrogen-**Ocular adverse reaction observed with this drug include retinal vascular thrombosis, dry eye, migraines and pseudotumor cerebri (24). The exact cause has not been proven, but may be associated with steepening of the corneal curvature, corneal edema from hypoxia, and decreased aqueous component of the pre-corneal tear film that leads to dry eye (5). Micro-vascular complications may be related to changes in retinal vasculature, enhanced platelet adhesiveness, or increase in fibrinogen and clotting factors (5).

3) **Hormone replacement therapy (HRT) with Progesterone-** Hormone receptor sites are located on meibomian glands. Physiological changes can cause alterations in the tear film, causing dry eye and contact lens intolerance, which are common side effects of this medication. Abnormal vision, visual disturbances and diplopia are generally the effects observed with this drug (25).

4) **Leuprolide acetate (Lupron)** - Administration of

Lupron leads to ocular side effects of temporary blurred vision for several hours up to three weeks. This is also known to cause pseudotumor cerebri and retinal vascular occlusions owing to its thromboembolic property (2, 26).

5) **Tamsulosin (Flomax)** - The most critical ocular side effect of this medication is known as intraoperative Floppy Iris syndrome (IFIS), which can cause complications to occur during cataract surgery (27). Although the precise mechanism by which tamsulosin can lead to IFIS remains unknown, Chang et al. (28) suggest that tamsulosin has a high affinity and specificity for the α_{1A} adrenergic receptor, which is thought to be the dominant receptor in the iris. It is important for the patient to inform their eye surgeon that they are on this medication prior to cataract surgery, to allow the surgeon to take additional measures during surgery including using iris hooks, iris dilator rings or viscoelastic substances to help keep the iris from intra operative miosis or iris prolapsing into the phacoemulsification incisions (2).

6) **Sildenafil (Viagra)** - It is a potent drug for Erectile Dysfunction which can cause a bluish tinge to objects, blurred vision and hypersensitivity to light. These symptoms are reversible and last a few minutes to several hours. Few cases of anterior ischemic optic neuropathy and non-arteritic ischemic optic neuropathy have been reported which can cause permanent vision loss (2). This has been attributed to inhibition of PDE6 mediated photo-transduction process (29).

E) Central nervous system (CNS) agents

Central nervous system (CNS) agents are becoming the most commonly prescribed class of medication in the world. In general, visual acuity may be inexplicably reduced, color vision altered, pigmented deposits may be found on the endothelium or lens capsule and optic neuritis may occur (30).

1) **Antipsychotics-** Use of these drugs leads to blurred vision, decreased accommodation and mydriasis (2). These symptoms are transient and dose-dependent. Reduced tearing and dry eye may also result from the anticholinergic effects.

a) **Chlorpromazine-** Chlorpromazine, at high dosages, can commonly cause abnormal pigmentation of the eyelids, inter-palpebral conjunctiva and cornea. It can also cause a more worrisome but rare visual impairment, namely corneal oedema (31).

Fig 4: No corneal endothelial deposits seen associated with lenticular deposits (32).

Pigment deposits can occur on areas of the bulbar conjunctiva that are exposed to UV radiations.

UV protection was found unsuccessful to reduce the prevalence and these patients should simply be monitored on a yearly basis. Also, retinal and macular damage have been reported in higher doses (24). This can lead to permanent visual acuity and visual field loss if not closely monitored. However, some of these changes may be reversible if detected early, with discontinuation of drugs or giving symptomatic medication.

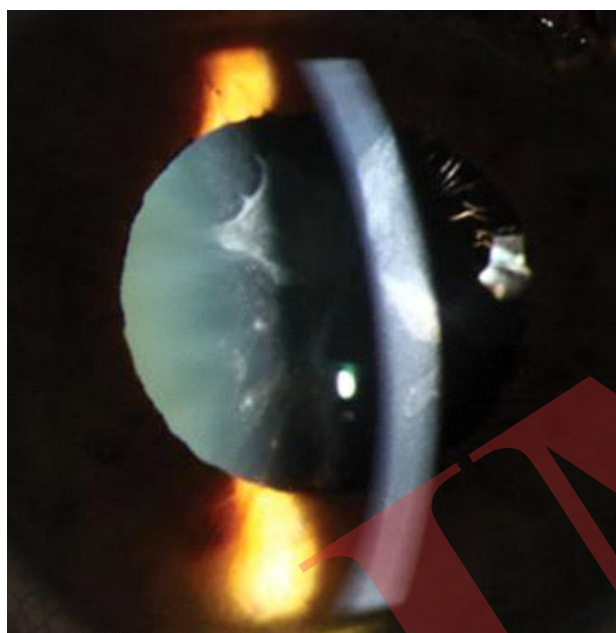


Fig 3: Stellate Pattern of Lenticular Deposits (21)

a) Lithium- Lithium has been reported to cause downbeat jerk nystagmus which may not even be reversed when the drug is stopped (4). Blurred vision sometimes occurs due to cortical involvement. Other ocular complications include, keratitis sicca, contact lens intolerance and diplopia. One bothersome potential adverse effect of lithium is eye irritation, usually noted during the first few weeks of treatment (16). The explanation behind this uncommon finding could be the increased sodium content of the lacrimal fluid, a phenomenon probably related to the presence of sodium-chloride co-transport in human lens epithelial cells, as recently demonstrated by Lauf et al. (18) This problem is usually shortlived and can be resolved even faster if the patient uses over-the-counter artificial tears as needed.

b) Phenothiazines: The most commonly documented retinal lesion secondary to phenothiazines is pigmentary retinopathy. Phototoxic processes are believed to be involved in both pigmentary retinopathy and retinal degeneration. It is postulated that antipsychotics, by their anti-dopaminergic actions, tend to prevent the beneficial effect of dopaminergic mechanisms on the life-regulatory functions of retinal tissues (30).

2) Antianxiety drugs

Ocular side effect like blurred vision and diplopia are usually rare and reversible with antianxiety drugs (24). Use of diazepam (Valium) sometimes produces mydriasis. Allergic conjunctivitis may onset after 30 minutes due to antigenic factors in the drug (2).

3) Antidepressants

It can cause transient and reversible symptoms of blurred vision mainly due to the anticholinergic effect of these medications and is usually a consequence of both cycloplegia and mydriasis (30, 33). Clinicians should use caution with sympatho-mimetics along with tricyclics and also with monoamine oxidase (MAO) inhibitors. TCAs can induce glaucomatous attacks in predisposed individuals. This is mainly due to the anti-cholinergic action of these medications, and to the subsequent mydriasis and cycloplegia (34). SSRIs have been associated with mydriasis, increased IOP and angle-closure glaucoma (35,36). The explanation for these adverse effects could be derived from the multiple action of SSRIs, with inter-individual variations, culminating in a pupillary dilatation and a relative blockade of the angle of the anterior chamber via anticholinergic or noradrenergic effects, and serotonergic effects (37). SSRIs may cause mydriasis via at least two mechanisms: 1. noradrenergic or anti-cholinergic effects resulting in pupillary dilatation; 2. stimulation of the 5-HT₇ receptors located within the iris musculature and the subsequent relaxation of the sphincter muscle of the pupil (33).

4) Sedatives

In patients using barbiturates, ptosis, diplopia and nystagmus are commonly noticed (38).

5) Anticonvulsants

Phenytoin and **carbamazepine** are very commonly prescribed as anticonvulsant, which may cause abnormal colour perception, nystagmus (39). Carbamazepine works by inhibiting voltage-dependent sodium channels (40). It commonly induces diplopia and gaze-evoked nystagmus, but it rarely leads to gaze palsies, downbeat or periodic alternating nystagmus (41-42).

6) CNS Stimulants are reported to cause accommodative dysfunctions and blurred vision due to mydriasis (43).

7) Antimigraine Agents

Not many side effects have been found with antimigraine agents. However corneal opacities were reported in dogs with newer drugs. Thus, it is best to take a careful history and monitor any changes (2).

Topiramate is a drug used for epilepsy and migraine prophylaxis. It causes acute transient myopia with shallowing of the anterior chamber which is a rare idiosyncratic response (44).

The dystonic effects of certain psychotropic medications (antipsychotics, carbamazepine, topiramate and possibly escitalopram) are of common concern in psychiatry. More often than not, they are of acute onset, but cases of tardive dystonia are also well documented in the literature (45). Acute dystonias have a complex aetiology; they can be secondary to dopamine receptor blockade, but other mechanisms are likely to play a role as well.

F) Anti-Malaria medications

Antimalarial drugs like Chloroquine and Hydroxychloroquine have visual side effects of decreased accommodation, corneal whorls and scotomas. Ocular side effects include a "bull's-eye" maculopathy with attenuated retinal vessels. Patients may have a yellow, green or blue tinge to their visual field with colored halos around light². Hydroxychloroquine binds to melanin, accumulates in the RPE, and remains there for long periods of time. It is directly toxic to the RPE, causing cellular damage and atrophy. This occurs due to disruption of RPE metabolism, specifically from lysosomal damage, and reduced phagocytic activity toward shed photoreceptor outer segments. Accumulation of photoreceptor outer segments leads to RPE degeneration, migration into the outer retina, and finally photoreceptor loss (46).

Transients and reversible corneal changes occur typically when patient receives more than 250g daily (31). It is important for all patients on this medication to get a baseline visual field and fundus examination with routine follow ups.

G) Rheumatological drugs

NSAIDs like ibuprofen and indomethacin have visual side effects that include vision changes, scotoma, photophobia, diplopia, color vision changes and rarely toxic optic neuropathy. Adverse ocular reactions include corneal vortex keratopathy (indomethacin), pseudotumour cerebri, optic neuritis and macular edema. Cases of retinopathy have been associated with NSAIDs and especially indomethacin due to pigmentary changes of the macula and other areas of the retina causing symptoms of blurred vision. Depending on the amount of retinal involvement, the electroretinogram (ERG) and electrooculogram (EOG) can be normal or abnormal (47).

Indomethacin is one of the most potent NSAIDs that has been associated with cases of corneal

opacities resembling chloroquine keratopathy and blurred vision, especially when used long term. Symptoms associated with the corneal opacities can range from mild light sensitivity to frank photophobia. These corneal changes diminish or disappear within 6 months of discontinuing indomethacin (47).

H) Pulmonary Disease Drugs

1) Steroids-

Inhalers have been linked to posterior and sub capsular cataracts, delays corneal healing, increased intraocular pressure and exacerbation of glaucoma in susceptible individuals.⁷ Glucocorticoid-induced gene transcription events in lens epithelial cells, and also other intraocular or systemic cells, likely interact to generate steroid cataracts (8). It causes stabilization of lysosomal membranes and accumulation of polymerized glycosamino-glycans (GAGs) in the trabecular meshwork, they become hydrated, producing "biologic edema" and increased outflow resistance, leading to increased intraocular pressure and glaucoma (9-10).

The pathogenesis of steroid-induced cataract may involve multiple mechanisms. One mechanism that is proposed for the corticosteroid-induced PSC is the formation of covalent adducts of the steroid molecule with the lysine residues of lens particles resulting in lens opacities (48). Another proposed mechanism is the inhibition of the sodium-potassium pump in the lens epithelium, leading to an accumulation of water within the lens fibres and agglutination of lens proteins. Other theories postulate that PSC development secondary to corticosteroid use involves elevation of glucose in the plasma and aqueous humor, increased cation permeability, inhibition of glucose-6-phosphate dehydrogenase, inhibition of ribonucleic acid synthesis, and loss of lens ATP. It is therefore plausible that multiple mechanisms are responsible for the development of PSC in patients treated with corticosteroids (47).

2) Mast Cell Stabilizers-

- **Nedochromyln sodium** (Inhaler Tilade) has been associated with conjunctivitis (49).

3) Antituberculosis Medications

An uncommon but serious complications of anti tuberculosis drug therapy is acquired optic neuropathy (24).

- a) Isoniazid and Ethambutol can cause retro-bulbar optic neuritis (43) causing blurred vision, decreased visual acuity, central scotomas, and loss of red-green color vision (50). Although uncommon at standard doses, optic neuritis is the most important potential side effect of thambutol. Retrobulbar neuritis is the most common, with involvement of either the axial

fibers or less commonly peri-axial fibers, and a mixed pattern on occasion (48,51). Mitochondrial dysfunction leading to optic neuropathies is getting recognized a lot more as a spectrum of conditions that reach a similar end point (48,52).

b) Ethambutol (Myambutol), Rifampicin (Rifadin), Isoniazid (Nydrazid), which has been associated with complaints of transient and reversible accommodation impairments (53).

c) Rifampicin: produce conjunctivitis and orange staining of contact lenses (54). These discolorations may be bothersome to the patient but do not require medical attention.

I) Decongestants

- **Phenylephrine**- may cause rebound miosis and decrease mydriasis (54)

J) Bisphosphonates

Fosamax, a bisphosphonate that is prescribed for postmenopausal women to prevent calcium bone loss, can cause orbital inflammation, uveitis and scleritis (55). The proposed mechanism of ocular inflammation is an idiosyncratic γ Δ T cell cytokine release involving IL-1 and IL-6 caused by bisphosphonates' similar structure to pyrophosphate molecules (56,57).

CONCLUSION

It can be concluded that many systematic drugs can produce ocular and visual side effects which range from mild to severe and can be even vision threatening. A careful and detailed case history is necessary to be aware of patient's medical history. It is very important that these ocular side effects from systemic drug use be reported and addressed timely.

These visual side effects should be recognized at the earliest to minimize serious complications and to plan appropriate intervention by modification of dosage or use of alternative drugs.

REFERENCES

1. Blomquist P, Palmer B. Ocular Complications of Systemic Medications. *The Am J Med Sci*. 2011;342(1):62-69.
2. Wren V.Q. Ocular & Visual side Effects of systemic Drugs- Clinically Relevant Toxicology and patient Management. *J. Behav. Optom*. 2000;11(6):149.
3. Mycek MJ, Harvey RA, Champe PC. *Lippincott's Illustrated Reviews: Pharmacology*, 2nd ed. Philadelphia: Lippincott-Raven, 1997.
4. Gaudana R, Ananthula H, Parenky A, Mitra A. Ocular Drug Delivery. *The AAPS Journal*. 2010;12(3):348-360.
5. Bartlett JD. Ophthalmic toxicity by systemic drugs. In : GCY Chiou, ed *Ophthalmic Toxicology*, 2nd ed. Michigan: Taylor and Francis, 1999:225-83.
6. Maus M. Ocular manifestations of systemic disease. *Curr Opin Ophthalmol*. 1998;9(6):61-63.
7. Fan D. Ocular-Hypertensive and Anti-inflammatory Response to Rimexolone Therapy in Children. *Arch. Ophthalmol*. 2003;121(12):1716.
8. James ER. The Etiology of Steroid Cataract. *J Ocul Pharmacol Ther*. 2007;23(5):403-20.
9. Francois J. Tissue culture of ocular fibroblast. *Ann Ophthalmol*. 1975 Dec;7(12):1551-1554.
10. Francois J, Victoria-Troncoso V. Mucopolysaccharides and pathogenesis of corticosteroid glaucoma. *Klin Monatsbl Augenheilkd*. 1974 Jul;165(1):5-10.
11. Peponis V, Kyttaris VC, Chalkiadakis SE, Bonovas S, Sitaras NM. Ocular side effects of anti-rheumatic medications: what a rheumatologist should know. *Lupus*. 2010;19(6):675-682.
12. Sandhya N. Ocular adverse effects of common systemic medications. *Kerala J Ophthalmol*. 2012;24:27-39.
13. Yilmaz S, Tuncer E, Alioglu E, Dereli T, Turk U, Turk B. Amiodarone-induced multiorgan toxicity with ocular findings on confocal microscopy. *Middle East Afr J Ophthalmol*. 2015;22(2):258.
14. Moorthy RS, Valluri S. Ocular toxicity associated with systemic drug therapy. *Opin Ophthalmol*. 1999;10(6):438-46.
15. Jaanus SD, Bartlett JD, Hiefr JA. Ocular effects of systemic drugs In : Bartlett JD and Jaanus SD. *Clinical Ocular pharmacology* 3rd ed. Boston: Butterworth. Heinemann. 1995:957:1006
16. Anticoagulants/antiplatelets/antithrombotics. *Reactions Weekly*. 2019;1751(1):38-38.
17. Wymore J, Carter J. Chlorpropamide-Induced Optic Neuropathy. *Arch Intern Med*. 1982;142(2):381-381.
18. Fraunfelder FF. Drug-induced ocular side effects. *Folia Ophthalmol JPN*. 1996;47(7):770-73.
19. Paterson C. Effects of Drugs on the Lens. *Int Ophthalmology Clinics*. 1971;2(2):63-98.
20. Novack G. Ocular toxicology. *Curr Opin Ophthalmol*. 1994;5(6):110-14.
21. Review of optometry. Cataracts secondary to

- medication are usually asymmetric, perhaps due to unequal deposition of medication in the crystalline lens. [image on internet] Published , 2016January 15 [cited 2019 june 22] available from <https://www.reviewofoptometry.com/article/the-minds-eye-ocular-complications-of-psychotropic-medications>
22. Chylack LT. Cataracts and inhaled corticosteroids. *N Eng J med* 1997;337:46-8
 23. Krishnaswami A, Ravi-Kumar S, Lewis JM. Thiazolidinediones: a 2010 perspective. *Perm J*. 2010;14(3):64-72.
 24. Levine L. Optometrically relevant side effects of the systemic drugs most frequently prescribed in 1991. *J Behav Optome* 1992;3(5):115-19.
 25. Schaumberg D. Hormone Replacement Therapy and Dry Eye Syndrome. *JAMA* 2001;286(17):2114.
 26. Fraunfelder FT, Edwards R. Possible Ocular Adverse Effects Associated With Leuprolide Injections. *JAMA*. 1995;273(10):773-774.
 27. Zaman F, Bach C, Junaid I, et al. The floppy iris syndrome - what urologists and ophthalmologists need to know. *Curr Urol*. 2012;6(1):1-7.
 28. Chang DF, Campbell JR. Intraoperative floppy iris syndrome associated with tamsulosin. *J Cataract Refract Surg*. 2005;31:664-673.
 29. Laties A1, Zrenner E. Viagra (sildenafil citrate) and ophthalmology. *Prog Retin Eye Res*. 2002 Sep;21(5):485-506.
 30. Richa S, Yazbek J. Ocular Adverse Effects of Common Psychotropic Agents. *CNS Drugs*. 2010;24(6):501-526.
 31. Hansen TE, Casey DE, Hoffman WF. Neuroleptic intolerance. *Schizophr Bull* 1997; 23 (4): 567-82
 32. Jain D, Arunan SM, Vedachalam A. Anterior Segment Involvement in Antipsychotics - An Unusual Presentation. *DJO* 2018;29:68-69.
 33. Malone Jr DA, Camara EG, Krug Jr JH. Ophthalmologic effects of psychotropic medications. *Psychosomatics* 1992 Summer; 33 (3): 271-7
 34. Ritch R, Krupin T, Henry C, et al. Oral imipramine and acute angle closure glaucoma. *Arch Ophthalmol* 1994; 112 (1): 67-8
 35. Costagliola C, Parmeggiani F, Sebastiani A. SSRIs and intraocular pressure modifications: evidence, therapeutic implications and possible mechanisms. *CNS Drugs* 2004; 18 (8): 475-84
 36. Costagliola C, Mastropasqua L, Capone D, et al. Effect of fluoxetine on intraocular pressure in the rabbit. *Exp Eye Res* 2000 May; 70 (5): 551-5
 37. Schmitt JA, Riedel WJ, Vuurman EF, et al. Modulation of the critical flicker fusion effects of serotonin reuptake inhibitors by concomitant pupillary changes. *Psychopharmacology (Berl)* 2002 Apr; 160 (4): 381-6
 38. Peragallo J, Biousse V, Newman N. Ocular manifestations of drugs and alcohol abuse. *Curr Opin Ophthalmol*. 2013;24(6):566-73
 39. Roff Hilton E, Hosking S, Betts T. The effect of antiepileptic drugs on visual performance. *Seizure*. 2004;13(2):113-28.
 40. Jo S, Bean BP. Sidedness of carbamazepine accessibility to voltage-gated sodium channels. *Mol Pharmacol*. 2014 Feb;85(2):381-7.
 41. Hadjikitidis S, Morgan JE, Wild JM, et al. Ocular complications of neurological therapy. *Eur J Neurol* 2005 Jul;12(7):499-57
 42. Chrousos GA, Cowdry R, Schuelein M, et al. Two cases of downbeat nystagmus and oscillopsia associated with carbamazepine. *Am J Ophthalmol* 1987;103:221-4
 43. To HT, Townsend JC. Ocular toxicity of systemic medications: a case series. *J Am Optom Assoc* 2000;71:29-29
 44. Desai CM, Ramchadani SJ, Bhopale SG, Ramchandani SS. Acute myopia and angle closure caused by topiramate, a drug used for prophylaxis of migraine. *Indian J Ophthalmol*. 2006;54:195-7
 45. Hansen TE, Casey DE, Hoffman WF. Neuroleptic intolerance. *Schizophr Bull* 1997;23(4):567-82
 46. Yam JC, Kwok AK. Ocular toxicity of hydroxychloroquine. *Hong Kong Med J*. 2006 Aug;12(4):294-304
 47. Peponis V, Kyttaris VC, Chalkiadakis SE, Bonovas S, Sitaras NM. Ocular side effects of antirheumatic medications: what a rheumatologist should know. *Lupus* 2010;19(6):675-682
 48. Chylack LT. Cataracts and inhaled corticosteroids. *N Engl J Med*. 1997;337:46-48
 49. Castillo M, Scott NW, Mustafa MZ, Mustafa MS, Azuara-Blanco A. Topical antihistamines and mast cell stabilisers for treating seasonal and perennial allergic conjunctivitis. *Cochrane Database Syst Rev*. 2015 Jun 1;(6):CD009566.
 50. Kokkada SB, Arthakur R, Nataranjan M, Palaian S, Chhetri AK, Mishra P. Ocular side effects of

- ntitubercular drugs-a focus on prevention, early detection and management .Kathmandu Univ Med J.2005 Oct-Dec ;3(4):438-41
51. Koul Pa.Ocular toxicity and ethambutol therapy:Timely recaution.Lung India 2015;32(1):1-3.
52. Chen L,Liang Y.Optic nerve neuropathy by ethambutol toxicity.Zhonghua Jie He HE Xi Za Zhi 1999;22:302-4
53. Jimenez Lucho VE,del usto R,Odel J. Isoniazid and ethambutol as cause of optic neurophy.Eur J Respir Dis 1987;70(5):729-33
54. Haddad N,Moyer N,Riley F.Mydriatic effect of Phenlephrine Hydrochloride.Am J.Med 1970;70(5):72-33
55. Umunakwe O.Diffuse ocular and orbital inflammation after zoledronate infusion-case report and review of the literature. Digit J.Ophthalmol.2017;23(4):18
56. McClung M, Harris ST, Miller PD, Bauer DC, Davison KS, Dian L, et al. Bisphosphonate therapy for osteoporosis: benefits, risks, and drug holiday.Am J Med. 2013 Jan;126(1):13-20.
57. Kunzmann V,Bauer E,Wilhelm M.Gamma/delta T- cell stimulation by pamidronate.N Engl J Med 1999;340:737-38SS