DOI:10.24041/ejmr2020.23

MYOEPITHELIAL CARCINOMA: A DIAGNOSTIC CHALLENGE IN CYTOLOGY

Ruchi Agarwal, Kulwant Singh, Anjali Sindhu, Parveen Rana, Swarn Kaur, Deepti Agarwal

Department of Pathology

Bhagat Phool Singh Government Medical College for Women, Khanpur Kalan, Sonepat (Haryana), India

Received on : 08-01-2020
Accepted on : 26-06-2019

Address for correspondence
Dr. Anjali Sindhu
Department of Pathology
Bhagat Phool Singh Government Medical College for Women, Khanpur Kalan, Sonepat, Haryana, India
Email: sindhuanjali.01@gmail.com
Contact no: +91-9812637121

ABSTRACT

Myoepithelial carcinoma is a very rare neoplasm of salivary gland constituting less than 1 % of all salivary gland neoplasm. The most common site of involvement is major salivary gland mainly parotid gland while minor salivary glands are rarely involved. In this case report, we are presenting a case of 29 year old male who presented with a gradually increasing pedunculated painless mass in the oral cavity for 3 months. Cytological diagnosis of cellular pleomorphic adenoma was given. Histopathological examination of excised mass confirmed the diagnosis of myoepithelial carcinoma.

KEYWORDS: Buccal, Myoepithelial carcinoma, Plasmacytoid, Minor salivary gland.

INTRODUCTION

Myoepithelial carcinoma (MC) is a very rare tumor of salivary gland having a reported incidence of less than 1% of all salivary gland tumors (1). Parotid gland is the most commonly involved site (48%-75%), followed by minor salivary glands and the submandibular gland (2-3). The tumour is composed of myoepithelial cells exhibiting both epithelial and smooth muscle differentiation. As myoepithelial differentiation is seen in many benign and malignant neoplasms of salivary glands and MC is a rare neoplasm with diverse cytological findings, it is very difficult to diagnose it alone on aspiration smears. Hence, histopathology and immunohistochemistry are necessary to make a definite diagnosis. With very limited data regarding the cytomorphological features, we present a case of MC of minor salivary gland in a young male along with its cyto-differentials.

CASE REPORT

A 29 old male presented with a slowly progressive swelling, not associated with pain in right oral cavity since 7 months in the surgery outpatient department. The past history and family history were insignificant. There was no history of tobacco chewing and smoking. No history of diabetes, tuberculosis and hypertension was present. The systemic examination was unremarkable. Local examination revealed a soft to firm, grayish pink in colour, non-tender, pedunculated lobulated mass in right buccal mucosa, measuring 1.5x1.5cm in size. On radiological examination, no involvement of the underlying bone was noted. Fine needle aspiration cytology smears revealed cellular smears with large tissue fragments and loosely cohesive groups of neoplastic cells intermixed with metachromatic stromal fragments. Tumour cells have abundant pale cytoplasm with ill defined cytoplasmic borders. The nuclei are eccentrically placed, moderately pleomorphic with inconspicuous nucleoli (Figure 1 a-f).

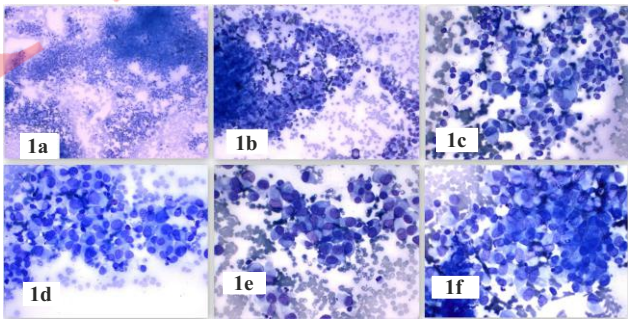

Fig 1: a: Photomicrograph of FNA from swelling shows cellular smears revealing large tissue fragments and cohesive group of neoplastic cells (Romanowsky stain 40X); b, c, d, e, f: Photomicrographs of FNA smears showing mainly plasmacytoid neoplastic cells arranged in loose cohesive clusters and singly scattered (Romanowsky stain 100X, 200X,400X)

Based on the above cytological features, the case was diagnosed as cellular pleomorphic adenoma with atypia. Wide local excision of the tumour was done and specimen was sent for histopathological examination (HPE). HPE revealed a tumor mainly composed of nest and lobules of atypical cells focally

separated by myxoid material. Tumour cells had moderate amount of eosinophilic cytoplasm, round to oval pleomorphic vesicular nuclei and prominent nucleoli. Cells at most places showed plasmacytoid appearance. Areas of necrosis with 6-8 mitosis/10 hpf were seen. Tumor cells were infiltrating into the surrounding tissue with focal ulceration of overlying mucosa. (Figure 2 a-d).

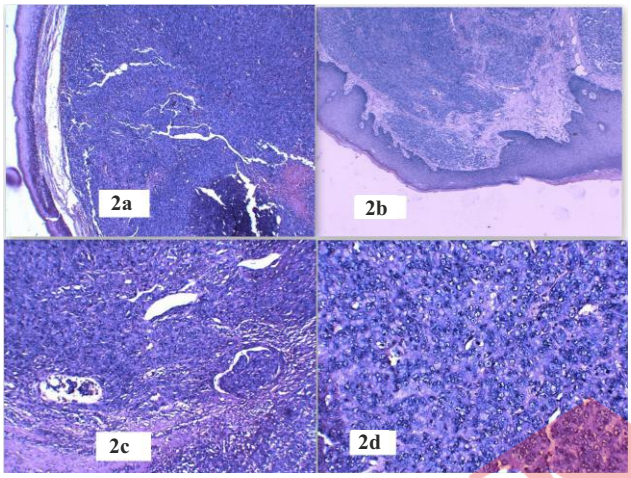

Fig 2 : a: Histopathology of oral swelling showing a nodular tumour below the oral mucosa (H&E 40X); b: Histopathology section showing invasion by the neoplastic cells (H&E 40X); c, d: Histopathology of oral swelling revealing sheets of round to oval tumour cells with large pleomorphic nucleus, vesicular chromatin and eosinophilic cytoplasm (H&E 100X, 400X)

Immunohistochemical profile revealed S100, CK and Vimentin positivity in the neoplastic cells. Tumour cells were negative for p63, HMB45 (Figure 3 a,b,c). Final diagnosis of myoepithelial carcinoma of minor salivary gland was given. Post operative period was uneventful. The patient was lost on follow up as he referred a higher centre for further workup.

DISCUSSION

Myoepithelial carcinomas, also known as malignant myoepitheliomas are very rare malignant neoplasms of salivary gland composed mainly of tumour cells showing myoepithelial differentiation. This was first described by Stromeyer et al in 1975 (4). Majority of cases of MC have been reported to arise in a preexisting benign mixed tumor and few arise de novo (5-6).

Studies conducted in the past, have reported the varied cytological characteristics of myoepithelial carcinoma. In the study by Di Palma et al (2) , out of ten cases of MC, tumour was located in the parotid gland in eight cases. The tumour cells were round epithelioid cells to spindle-shaped and stellate cells and displayed reactivity for high molecular weight keratins and smooth muscle actin. Chhieng and Paulino (7) reported four cases of MC, out of which, three cases were from the parotid gland, and one presenting as recurrent tumor in the minor salivary gland of the hard palate. The aspirates of two cases comprised of predominantly spindle cells, while one case had predominantly epithelioid cells and one case showed mixture of both spindle and epithelioid/plasmacytoid cells. Based on these cytological features, two cases were diagnosed as malignant spindle cell neoplasm, not otherwise specified and one case was interpreted as a pleomorphic adenoma with atypia. They observed that the presence of plasmacytoid/epithelioid cell type with marked nuclear pleomorphism has been found to be reliable diagnostic feature for MC in cases reported in the past.

Sehgal et al (8) reported a case of MC in a 37 year female who presented with an infra-auricular swelling. Cytological smears were markedly cellular. The neoplastic cells were arranged singly and in small groups showing nuclear overlapping. The tumor cells had epithelioid appearance with a moderate amount of dense, non-granular cytoplasm and mild nuclear pleomorphism. Cytological possibilities of cellular pleomorphic adenoma and myoepithelial cell neoplasm was given. Final diagnosis of MC was given after histopathological examination.

In the present case, plasmacytoid cell type with eccentric placed nuclei and abundant stromal fragments was observed. Although smears were cellular and tumour cells revealed mild nuclear pleomorphism, but other features of malignancy like coarse chromatin, prominent nucleoli, mitotic figures and necrosis were not found making the diagnosis of malignancy unlikely on cytological smears.

Grossly, these tumours are unencapsulated soft to firm multinodular masses with infiltrative margins and size ranging from 2-20 cm (9). The cut surface shows areas of haemorrhage, cystic degeneration and necrosis. Histologically, the tumour exhibits mostly nodular or solid sheet like pattern of neoplastic cells with intervening hyaline or myxoid stroma of variable amount. Tumour cells exhibit variety of cytological appearance including spindle, plasmacytoid, epithelioid, and clear cells, with one of these cell types being predominant (1). Infiltration of tumour cells into adjacent normal tissue is the most important histological feature to differentiate malignant from benign myoepithelial neoplasms and hence it should be considered the minimum requirement for diagnosis of MC (6).

Due to its wide cytomorphological features, MC poses a diagnostic challenge for the pathologist. The various differential diagnosis include pleomorphic adenoma,

oncocytic adenoma and mesenchymal neoplasms of smooth muscle or neural origin. The presence of plasmacytoid neoplastic cells with abundant stromal fragments and mild nuclear atypia favours the diagnosis of benign mixed tumour. Presence of cytological atypia should raise the suspicion of MC. Abundant eosinophilic cytoplasm in epithelioid cells may raise the possibility of oncocytic neoplasm as the differential diagnosis, however abundant granular cytoplasm and centrally placed nuclei of oncocytes can be helpful in distinction between the two entities. The predominance of neoplastic spindle cells in MC may be confused with mesenchymal neoplasms. Other ancillary studies, such as immunohistochemistry can be useful in the recognition of the myoepithelial differentiation of the neoplastic cells. The neoplastic cells show immunoreactivity to cytokeratin, S-100 protein, and smooth muscle actin, GFAP and calponin.

The clinical outcome of myoepithelial carcinoma is variable. Few studies done in the past reported long time patient survival in highly aggressive tumours while other studies reported early metastasis and death in patients with low grade tumours showing mild atypia (6-7,10). Due to rarity of this tumour, very limited treatment experience is available for it. Complete surgical resection is generally the treatment of choice. Large, multicentric studies need to be conducted to assess the role of chemotherapy and radiotherapy as the potential treatment modality for myoepithelial carcinoma.

CONCLUSION

Myoepithelial carcinoma of the salivary glands have a relatively high recurrence rate and metastasis rate. The current knowledge of myoepithelial carcinomas is limited because these have been underrecognized and underreported in the past. Hence, awareness and knowledge of its characteristic cytoarchitectural, histomorphological patterns and immunohistochemical profile is crucial for accurate identification.

REFERENCES

1. Ellis GL, Auclair PL. In Tumors of Salivary Glands. Atlas of tumor pathology. 3rd Ed.Washington, DC: AFIP; 1996.
2. Di Palma S, Guzzo M. Malignant myoepithelioma of salivary glands: clinicopathological features of ten cases. Virchows Arch A Pathol Anat Histopathol. 1993. 423(5):389-396.
3. Skalova A, Jakel KT. In Tumours of the salivary glands. WHO Classification of Tumours; Pathology and genetics of Head and Neck Tumours. Lyon, France: IARC Press; 2005.
4. Stromeyer FW, Haggitt RC, Nelson JF, et al. Myoepithelioma of minor salivary gland origin. Light and electron microscopical study. Arch Pathol Lab Med. 1975;99: 242-245.
5. Nagao T, Sugano I, Ishida Y, et al. Salivary gland malignant myoepithelioma: a clinicopathologic and immunohistochemical study of ten cases. Cancer 1998;83:1292-1299.
6. Savera AT, Sloman A, Huvos AG, et al. Myoepithelial carcinoma of the salivary glands: a clinicopathologic study of 25 patients. Am J Surg Pathol. 2000;24:761-774.
7. Chhieng DC, Paulino AF. Cytology of myoepithelial carcinoma of the salivary gland. Cancer. 2002;96:32-36.
8. Sehgal S, Goyal P, Singh S, et al. Fine-needle aspiration cytology of myoepithelial carcinoma of salivary gland: Diagnostic challenge to cytopathologist. J Cytol. 2013; 30(3): 207-210.
9. Crissman JD, Wirman JA, Harris A. Malignant myoepithelioma of the parotid gland. Cancer. 1977; 40(6):3042-3049.
10. Dardick I. Malignant myoepithelioma of parotid salivary gland. Ultrastruct Pathol. 1985;9:163-168.

How to cite this article : Agarwal R., Singh K., Sindhu A., Rana P., Kaur S., Agarwal D. Myoepithelial Carcinoma: A Diagnostic Challenge In Cytology. Era J. Med. Res. 2020; 7(1): 142-144.