

HISTOLOGICAL TOXICITY AND SEMINO-HORMONAL ALTERATIONS ON THE TESTIS OF MALE WISTAR RATS AFTER ORAL LEAD INDUCTION (RATTUS NOVERGICUS)

Adebola Opeyemi Adetunji, ObasiKosisochukwu K*

Department of Anatomy

College of Health And Medical Sciences, University of Ibadan, Oyo State, Nigeria

College of Health Sciences, University Of Nigeria Nsukka, Enugu State, Nigeria*

Received on : 08-08-2019

Accepted on : 14-09-2019

ABSTRACT

Lead exposure results in infertility and sterility in male professional workers. Here, we studied the histological toxicity and semino-hormonal Alterations on the Testis of Male Wistar Rats after Oral Lead Induction (*Rattus novergicus*). Eighty (80) male Wistar rats were grouped into four groups (1- 4) and further subdivided into 4 subgroups (A, B, C, and D) each containing five (n=5) rats depending on duration (3, 6, 9 and 12 weeks) and dosage of lead treatment. Control received 1 ml of distilled water daily. Group 2 received 0.5% lead daily, group 3 received 1.0% of lead daily and group 4 received 1.5% of lead daily respectively. Hormonal (Serum follicle stimulating hormone, Luteinizing hormone and Testosterone hormone levels), Semen and histological analysis using Gordon's and Sweet and Haematoxylin and Eosin Stains were observed. Results showed that significant reductions ($P<0.05$) in body weights were observed in treatment groups that were given Lead acetate for periods of 3,6, 9 and 12 weeks compared to the control. Histological examination of testis revealed that lead showed that exposure of male rats to 1.0% and 1.5% of lead for 9 weeks and 12 weeks induced severe tubular degeneration, disorganization in basement membrane, degeneration and atrophy in most seminiferous tubules, increased interstitial spaces, decreased leydig cells, necrosis and reduction in spermatogenic cells. Significant reductions ($P<0.05$) in semen and hormonal analysis was observed compared to control. In conclusion, the study showed that lead administration caused severe seminal and histo-hormonal alterations, therefore leading to reproductive toxicity in rats.

KEYWORDS: Lead, Testis, Reproduction, Histo-hormonal, Sperm parameters

INTRODUCTION

For the testis to properly function, it has to be dependent on the arrays of hormonal messengers acting through different hormonal pathways (1). To maintain the proper functioning of testicular cells; gonadotropins must play a big role (2). They are referred to as 'prime regulators of germ cell development'. Lead is considered to be a reproductive toxicants and or a disruptor of the endocrine system. In Nigeria, infertility is a major problem accounting to about 12 million infertile people (3-5).

Decreasing sperm counts are attributed to the harmful effects of environmental contamination by heavy metals (6). Heavy metals like lead adversely affect the male reproductive system; either by causing disruption in the hypothalamic-pituitary axis (HPA) or by directly affecting the process of spermatogenesis (7). Lead severely depletes semen quality; likewise impairment of sperm parameters like motility, morphology etc (8-9).

It was found that the mechanisms of lead induced cellular damage are generations of reactive oxygen species with subsequent stimulation of lipid peroxidation (16,23). Oxidative stress arises when there is a marked imbalance between the production and removal of these free radicals. Free radicals may therefore play a central role in lead induced testicular dysfunction (24).

Therefore, it was on this basis that we decided to investigate the histological toxicity and seminohormonal alterations on the testis of male Wistar rats after oral Lead induction (*Rattus novergicus*).

Ethical approval

This experiment was carried out in conformity with the rules and guidelines of the Animal Ethics Committee of the Babcock University Ilisan, Ogun State. The research was approved to be in compliance with the institutional animal care and Use committee (IACUC).

Address for correspondence

Dr. Adebola Opeyemi Adetunji

Department of Anatomy

College of Health And Medical Sciences,
University of Ibadan, Oyo State, Nigeria

Email: addturng1809@gmail.com

Contact no: +234-8038217080

Animal Grouping and Treatments

Eighty (80) weaned male Wistar rats with an average weight of 34g, were divided into four groups (1-4) and further subdivided into 4 subgroups each containing five (n=5) rats depending on the dosage and duration of treatment. Group 1 (1A, 1B, 1C, 1D) served as control received

1 ml of distilled water daily. Group 2 (2A, 2B, 2C, 2D) received 0.5% Lead acetate for three (3), six (6), nine (9), and twelve (12) weeks, Group 3 (3A, 3B, 3C, 3D) received 1.0% Lead acetate for 3, 6, 9, and 12 weeks, Group 4 (4A, 4B, 4C, 4D) received 1.5% Lead acetate for 3, 6, 9, and 12 weeks respectively. Treatment doses for Lead adopted in this study were administered using an orogastric cannula and the experiment was based on facts related to previously reported studies of its reproductive toxicity on Wistar rats. All animals were fasted overnight and body weight measured weekly using Electronic Weighing Balance.

Preparation of Treatment Solution

500g of Lead acetate manufactured by BDH Chemicals Ltd England was purchased from Yomi-Esthony Company, Ilorin. This was identified and confirmed at the Department Of Chemistry, Babcock University Ilisan, Ogun State.

Qualitative confirmation was done by diluting lead (Pb) with nitric acid to form solution of the lead acetate (25).

Sample Collection and Processing

On completion of treatments, rats for histological analysis were euthanized using 20 mg/kg body weight of ketamine intraperitoneally. Following a midline incision of the thoracic cavity, blood samples were collected via cardiac puncture into lithium heparinised bottles with the aid of a 2 ml syringe from all rats employed in the study. An abdominopelvic incision was made to excise the testes and epididymis of each rat was excised. The testis was processed for histopathology while the epididymis was used for semen analysis. The serum was separated by centrifugation at 3000 rpm for 15 minutes. Histological staining was carried out in paraffin wax embedded sections and stained with Haematoxylin and Eosin using the methods described by (10) and a special stain Gordon's and Sweet was used to highlight testicular reticular fibres.

Hormonal assay

Serum testosterone, follicle stimulating hormone (FSH) and Luteinizing hormone (LH) concentration were estimated using Accu Bind ELISA Microwell by Monobind Inc. Lake Forest, CA92630, USA.

Evaluation of luteinizing hormone (LH) levels

Microplate wells were formatted for each serum reference, control and specimen to be assayed in

duplicate. 0.05ml (50µl) of the appropriate serum reference, control or specimen was pipetted into assigned well. 0.1 ml (100µl) of LH-Enzyme reagent was added to all wells. The microplate was swirled gently for 20-30 seconds for proper mixing. The microplate was incubated at room temperature for 60 minutes.

The content of the microplate was discarded by decantation (using absorbent paper to blot the plate dry). 350µl of serum buffer was added and decanted. The procedure was done replicated thrice for proper washing of microplate. 0.100ml (100µl) of working substrate was added to all wells. The reagents were added in the same order to minimize reaction time differences between wells. The plate was incubated at room temperature for 15 minutes. 0.005ml (50µl) of stop solution was added to each and was mixed for 15-20 seconds. Finally, each absorbent was read at 450nm in a microplate reader (using a well reference wavelength of 620-630 nm to minimize well imperfection).

Evaluations of follicle stimulating hormone (FSH) levels

The Microwell follicle stimulating hormone (FSH) EIA is a solid-phase enzyme immunoassay based on the 'sandwich' principle. Two separate antibodies directed against distinct antigenic determinants of the FSH molecule were utilized in the assay. The FSH present in the test sample reacted simultaneously with one antibody immobilized on the microwell surface and with another antibody conjugated to horseradish peroxidase enzyme forming an Ab-Ag Ab Enzyme complex on the microwell surface.

The unbound conjugate was removed by washing while colour development reagents (substrates) were added leading to a colour change upon exposure. Colour intensity was a reflection of the amount of bound anti-FSH enzyme conjugate and it was proportional to the concentration of FSH in the specimen within the dynamic range of the assay. After reaction stopped, colour measurement was done using a spectrophotometer at 450 nm.

Determination of Serum Testosterone Levels

Blood testosterone levels were measured by Enzymelinkedimmunosorbant assay (ELISA) by (Monobind Inc. Lake Forest, CA 92630, USA).

Semen Analysis

Rat epididymis was placed in normal saline and used for evaluation of sperm quality (i.e. sperm count^[11], sperm motility^[12] and sperm Progressivity (SLOW and FAST).^[13] The concentration of spermatozoa was determined using the improved Neubauer Chamber Haemocytometer (Deep 1/10 mm, LABART, Germany).

Light microscopy

For light microscopic studies, the testis sections on glass slides were captured using Olympus binocular research microscope (Olympus, New Jersey, USA) which was connected to a 5.0 MP Amscope Camera (AmscopeInc, USA).

Statistical Analysis

Data collected were analyzed using two-way analysis of variance (ANOVA) followed by Tukey's (HSD) multiple comparison test with the aid of SPSS (V20; USA). Data were presented as means \pm SEM (standard error of mean). P value ($p < 0.05$) was considered statistically significant. All graphs were drawn using the GraphPad Prism v.6 (GraphPad Software Inc., USA).

Results

Lead altered the general physical appearance of rats

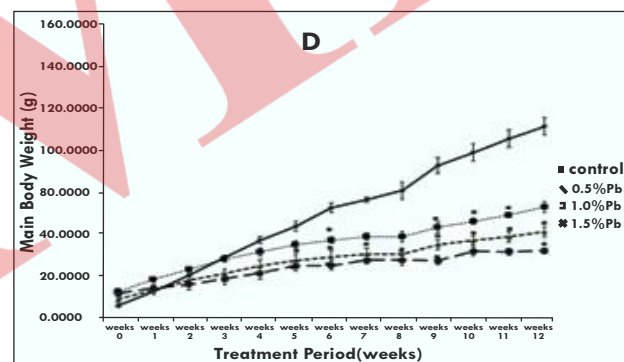
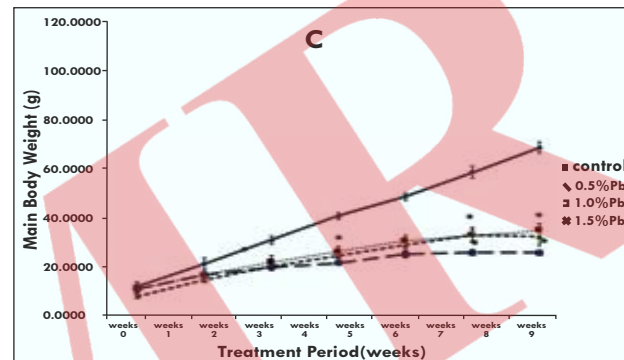
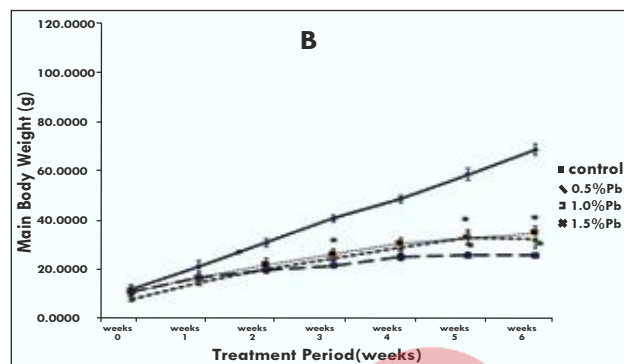
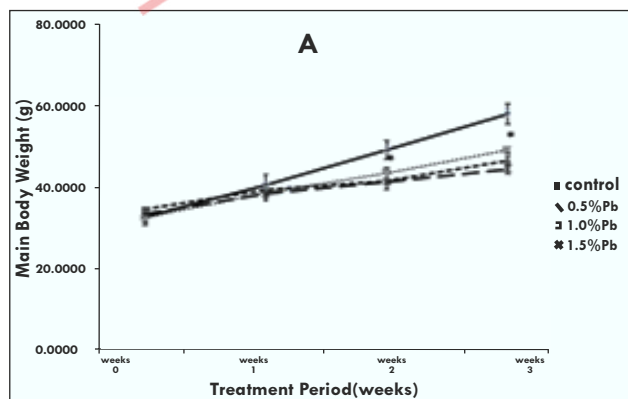
Following close observations, the rats in control groups remained active and healthy with normal feeding behaviour and consumed water regularly while rats in the treated groups were less active, highly irritable with mild to severe alopecia were observed in the groups administered 1.0% and 1.5% of lead acetate over periods of 9 and 12 weeks than their respective controls.

Testicular and Scrotal Gross appearance after lead acetate administration

Control animals scrotal sacs were normal in size, shape and colour, no distortions, highly vascularised and pinkish in colour. There was no sign of distortion as well. Lead treated groups showed reduced scrotal size with majority showing undescended testes, pale in appearance and less vascularised.

Lead acetate reduced body weights

Significant reduction ($P < 0.05$) in body weights was observed in the group administered 1.0% and 1.5% of lead acetate for a period of 3 and 6 weeks while significant reductions ($P < 0.05$) in body weights was observed in the group administered only 1.5% of lead for a period of 9 and 12 weeks respectively (Fig. 1).



Oral Lead Intoxication negatively affects Semen
 received lead for a 3 weeks period when compared to Analysis control while significant decrease ($P < 0.05$) was Significant decrease ($P < 0.05$) in sperm concentration observed in groups B-D that received Lead for count was observed in group D alone that received periods of 6, 9 and 12 weeks when compared to lead for a 6 weeks period when compared to control control (Fig. 2C). Significant increase ($P < 0.05$) in group (Fig. 2A) while significant decrease ($P < 0.05$) SLOW sperm progressive assessment was observed in sperm motility was observed in groups B-D that in group D alone that received lead for 3 and 9 weeks received Lead for 9 and 12 weeks period of time period when compared to control while a significant when compared to control (Fig. 2B). Significant increase ($P < 0.05$) was observed in groups B-D that decrease ($P < 0.05$) in FAST sperm progressive received Lead for periods of 6 and 12 weeks when assessment was observed in group D alone that compared to control group (Fig. 2D).

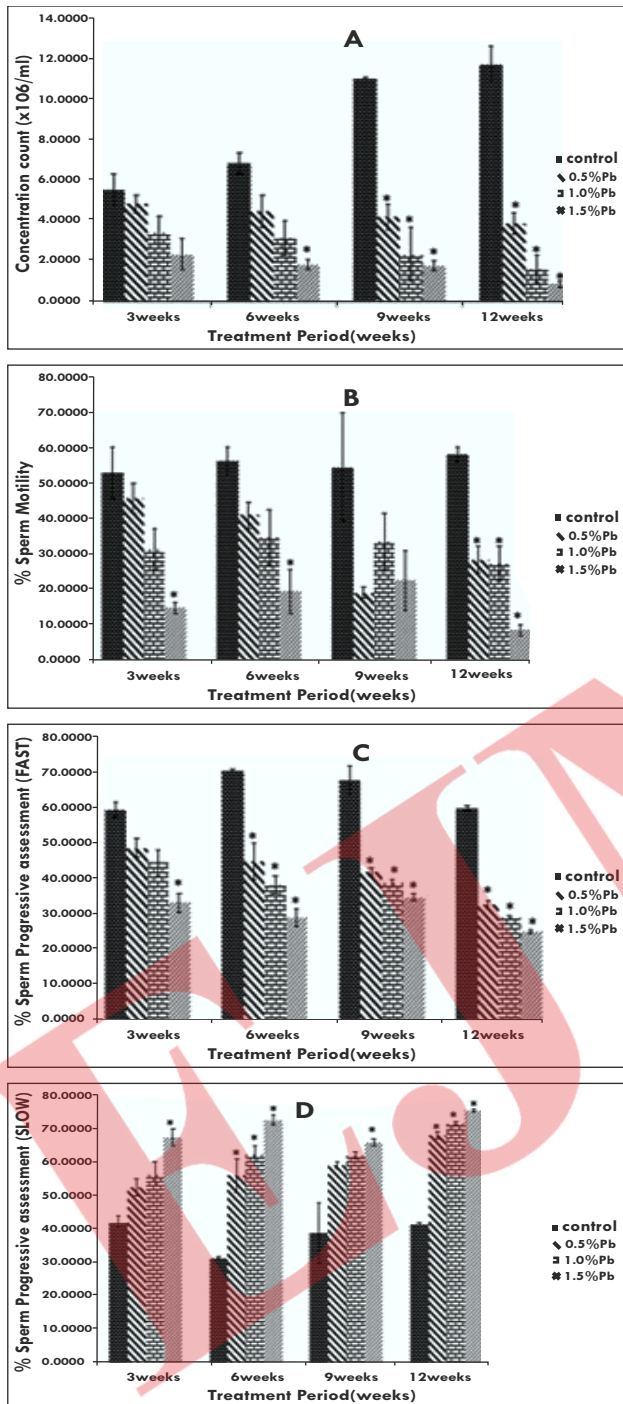


Fig 2: (A-D):showing The Semen Analysis Of Animals Treated With Varying Doses And Duration Of Lead Acetate At Varying Periods Of Treatment (3, 6, 9, And 12 Weeks) $(p<0.05)$ - Significantly Different Compared To Control Group

Lead accumulation altered hormonal balance and caused the disruption of the neuroendocrine system. Significant decrease ($P<0.05$) in serum follicle stimulating hormone (FSH) levels were observed in group C and D alone that received lead for a 6 and 9

weeks period when compared to control group while it significantly reduced ($P<0.05$) in groups B-D for rats that received Lead for a period of 12 weeks compared to control (Fig. 3A). Significant decrease ($P<0.05$) in serum Luteinizing hormone (LH) levels were observed in group B and D that received lead for a 6, 9 and 12 weeks period of time when compared to control group (Fig. 3B).

Significant decrease ($P<0.05$) in serum Testosterone levels was observed in group D alone that received Lead for a 6 weeks period of time when compared to control group while it significantly reduced in groups B-D for rats that received Lead for periods of 9 and 12 weeks compared to control group (Fig. 3C).

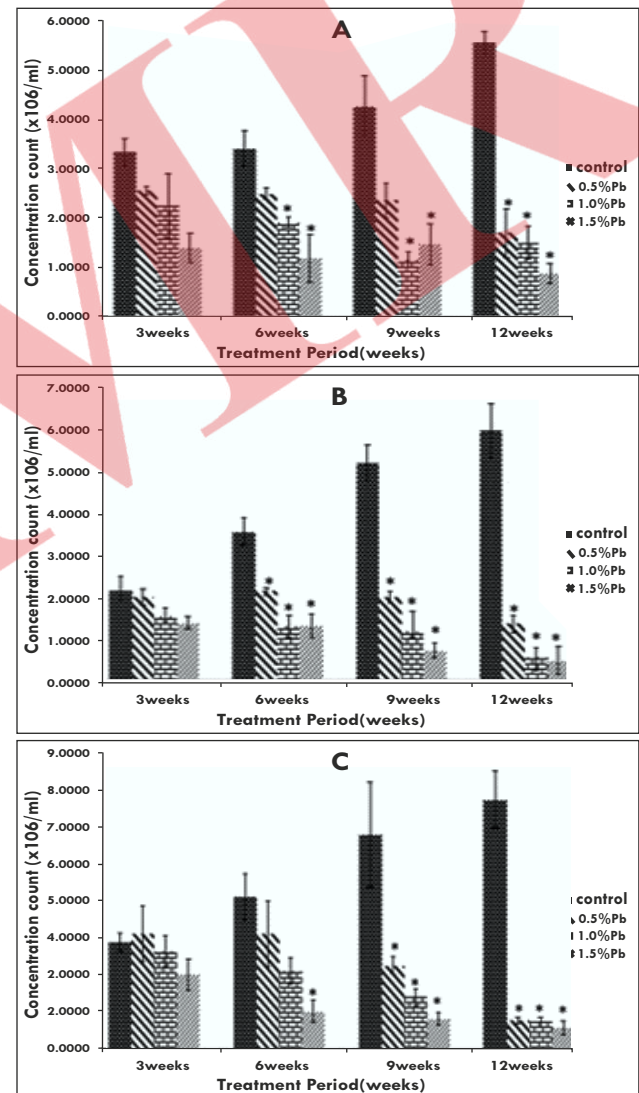


Fig 3 (A-C):Showing The Serum Hormonal Levels Of Animals Treated With Varying Doses And Duration Of Lead Acetate At Varying Periods Of Treatment (3, 6, 9, And 12 Weeks) $(p<0.05)$ - Significantly Different Compared To Control Group

Lead intoxication degenerates seminiferous tubules of Wistar rats using H & E Stain

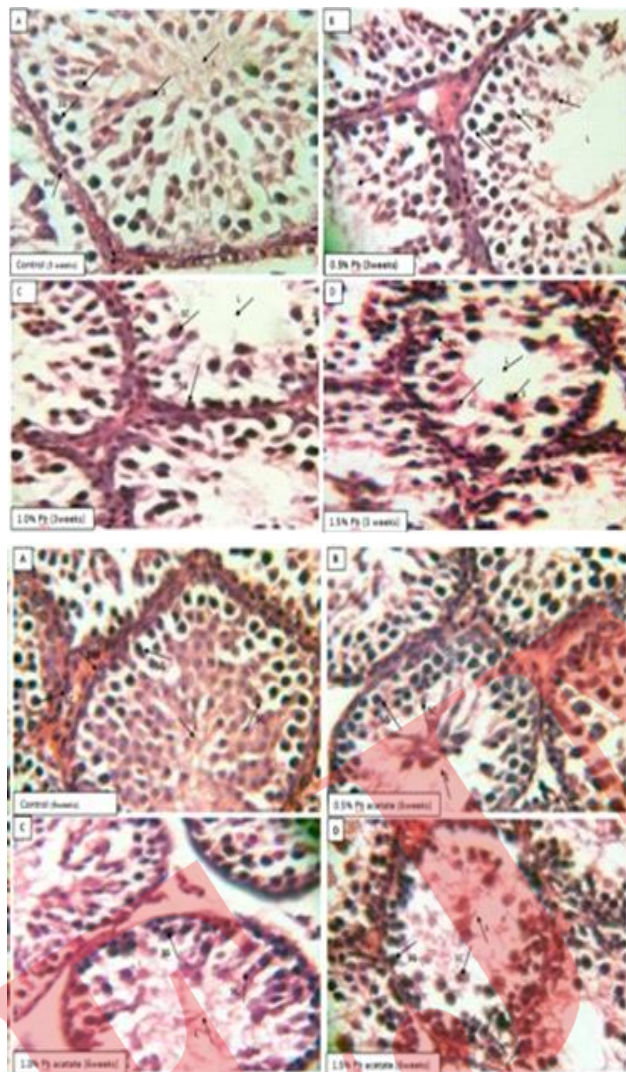


Fig 4A (3 and 6 weeks): General structure of the testes of animals treated with varying doses and duration of Lead acetate. SG Spermatogonia I-Interstitial space, BM-basement membrane, SC-spermatocytes, L-Lumen. LC-Leydig cells, S-Spermatids. H & E Stain. Mag. X400

Testicular cytoarchitecture of the control groups were in normal arrays. Groups given 0.5% and 1.0% of Lead showed degenerated seminiferous epithelium, reduced spermatogenic cells, widened lumen, absence of Sertolicells and thickened basement membrane while the group administered 1.5% Lead acetate for 3 and 6 weeks showed degenerated basement membrane and seminiferous tubule, vacuolation, widened lumen, little or no spermatogenic cells, mild maturation arrest, reduced Leydig cells and interstitial spaces with dilated and congested vessels.

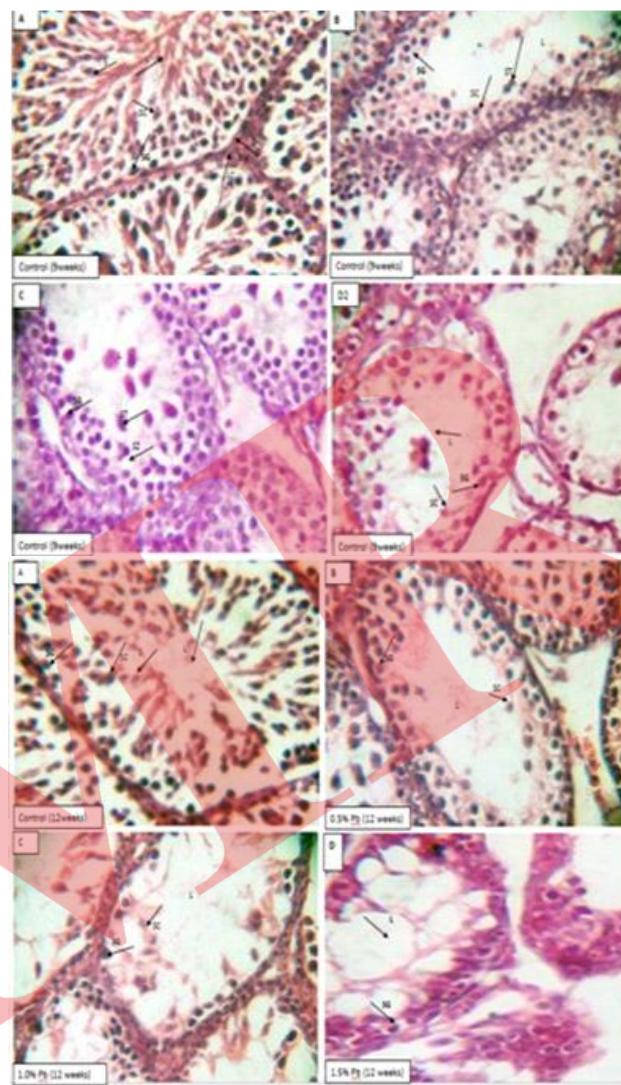


Figure 4B (9 & 12 weeks): General structure of the testes of animals treated with varying doses and duration of Lead acetate. SG Spermatogonia I-Interstitial space, BM-basement membrane, SC-Spermatocytes, L-Lumen. LC-Leydig cells, S-Spermatids. H & E Mag. X400.

Testicular cytoarchitecture of the control groups were in normal arrays. Groups given 0.5% and 1.0% Lead showed severe degenerated basement membrane, severe degenerated elongated seminiferous epithelium, very few spermatogonium and spermatogenic cells, widened lumen and absence of Sertoli cells while the group administered 1.5% Lead acetate for 9 and 12 weeks showed degenerated basement membrane, seminiferous epithelium and tubule, sloughed off germ cells, atrophy, severe vacuolation, presence of apoptotic cells, widened lumen, absence of spermatogenic cells and spermatocytes, severe maturation arrest, absence of Leydig cells, necrosis and degenerated interstitial space.

Lead intoxication degenerates seminiferous tubules of Wistar rats using Gordon and Sweet Stain

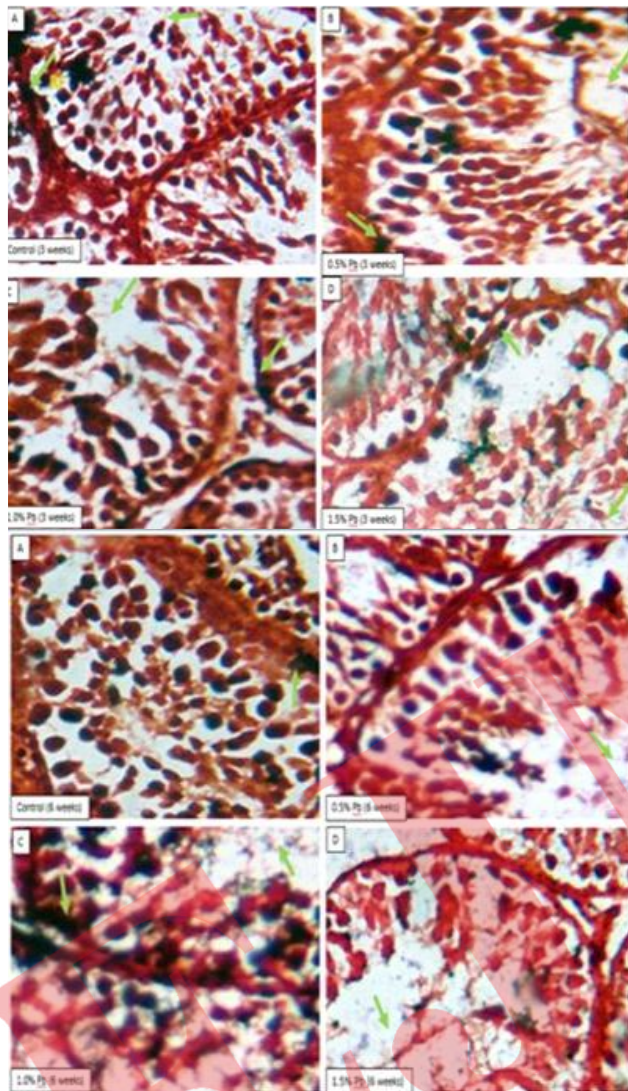


Fig 5A (3 and 6 weeks): General structure of the testes of animals treated with varying doses and duration of Lead acetate. SG-Spermatogonia I-Interstitial space, BM-basement membrane, SC-spermatocytes, L-Lumen. LC-Leydig cells, S-Spermatids. Gordon's and Sweet Stain. Mag. X400

Testicular cytoarchitecture of the control groups were in normal arrays. Groups given 0.5% and 1.0% Lead showed degenerated seminiferous epithelium, reduced spermatogenic cells, widened lumen, absence of Sertoli cells and thickened basement membrane while the group administered 1.5% Lead acetate for 3 and 6 weeks showed degenerated basement membrane and seminiferous tubule, vacuolation, widened lumen, little or no spermatogenic cells, mild maturation arrest, reduced Leydig cells and interstitial spaces with dilated and congested vessels.

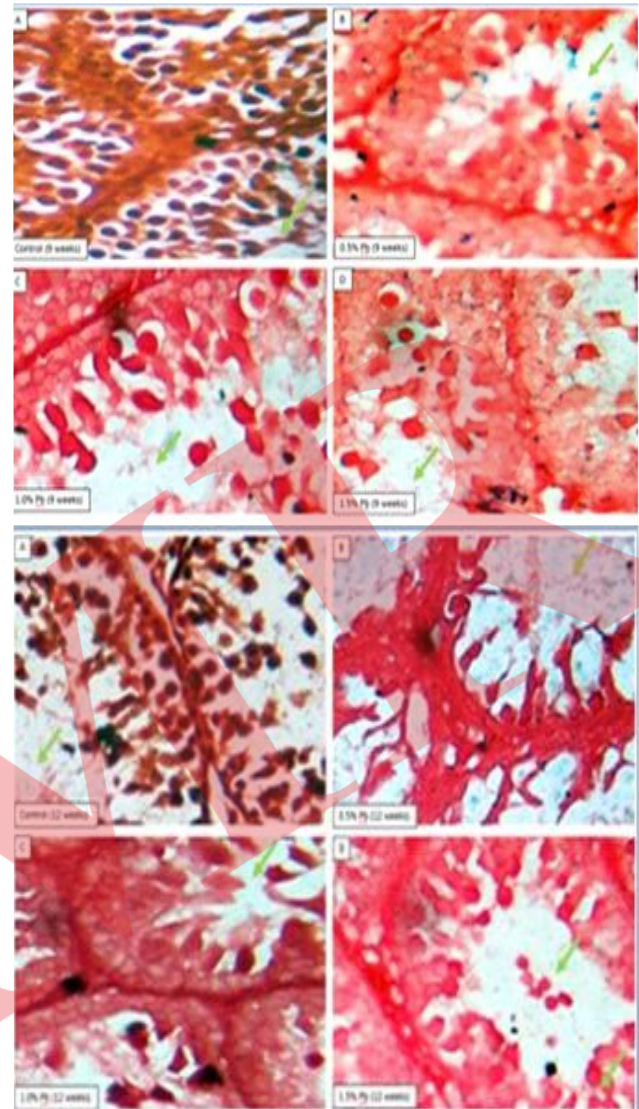


Fig 5B (9 and 12 weeks): General structure of the testes of animals treated with varying doses and duration of Lead acetate. SG-Spermatogonia I-Interstitial space, BM-basement membrane, SC-spermatocytes, L-Lumen. LC-Leydig cells, S-Spermatids. Gordon's and Sweet Stain. Mag. X400

Testicular cytoarchitecture of the control groups were in normal arrays. Groups given 0.5% and 1.0% Lead showed degenerated seminiferous epithelium, reduced spermatogenic cells, widened lumen, absence of Sertoli cells and thickened basement membrane while the group administered 1.5% Lead acetate for 9 and 12 weeks showed degenerated basement membrane and seminiferous tubule, vacuolation, widened lumen, disruption of spermatogenic cells, severe maturation arrest, severe necrosis, little or no Leydig cells and absence of interstitial spaces and dilated and congested vessels.

DISCUSSION

Pb has been related to a very broad range of dysfunctions physiobiochemically that leads to the induction of oxidative stress and release of reactive oxygen species, thereby playing detrimental roles in testicular damage (14).

In the present study oral administration of lead acetate on male rats affected the testes and caused histological and semina-hormonal changes and its exposure for a longer period of time had detrimental effects on reproduction and sperm parameters (15).

Significant reduction ($P < 0.05$) in body weights observed in the group administered 1.0% and 1.5% of lead acetate for a period of 6, 9 and 12 weeks were indicative of atrophic changes that had taken place in the testes. This was in agreement with (14) who reported testicular atrophy of rats treated with lead acetate. This was also in agreement with (13-18) who reported that testicular weights significantly declined in lead-treated mice and Wistar rats compared to control groups respectively, therefore highlighting increased catabolism and metabolic imbalance as one of the major causes of it.

Lead accumulation in the male accessory organs like the prostate and epididymis impaired sperm motility.^[1]

For infertility in males to be determined, proper evaluation of the hormonal levels is very useful determinant.^[3] Lead also causes hormonal imbalance by affecting the neuroendocrine system and disrupting the secretion of androgens from Leydig cells (19). The significant reduction in serum FSH, Testosterone and LH levels were apparent on a dose duration dependent manner. It corroborated with (16,20) who reported that Lead acetate had decreasing effects on testis steroidogenic function, serum gonadotropin levels and testosterone levels compared to control. These reductions altered hormonal balance and caused neuroendocrine system disruption.

The significant reductions in FAST sperm progressive assessment, sperm motility, sperm concentration and increase in FAST sperm progressive assessment observed in the groups administered Lead for a longer period of time and dosage were as a result of its devastating effects on sperm parameters. It was evident that lead interfered with the sperm production in the tubules as well as in the epididymis and produced degenerative changes in lead treated groups. This result corroborated (7-9, 21) who reported that mild lead exposure led to decrease in sperm parameters (sperm morphology, sperm concentration, poor semen viability and motility).

The severe disruption of spermatogenesis in men at any

stage of cell differentiation can lead to abnormal and decreased sperm count, impair the stability of sperm chromatin or damage sperm DNA (22). According to the histological analysis in this current study, It showed that exposure of male rats to 1.0% and 1.5% of lead for 9 weeks and 12 weeks induced cellular necrosis, severe tubular degeneration, disorganization in basement membrane, degeneration and testicular atrophy in most seminiferous tubules. This was in line with (20) who reported similar observations after lead administration on Wistar rat testis. These results were consistent with reports from hormonal and sperm parameters measured observed in this study.

CONCLUSION

In conclusion, the manifestations observed in this study include severe changes in histopathology, semen and hormonal parameters in the testis, affecting both spermatogenic and androgenic compartments. The results brought to the fore the association between lead intoxication and reproductive toxicity on a dose-duration dependent manner.

REFERENCES

1. De Kresten D. (1979). Endocrinology of Male Infertility. Brit. Med. Bullet. 35 (2):187-192.
2. Zabul J., Mierzejewski, W., Rogoza, A. Usefulness of examining gonadotropin hormones and testosterone in men with abnormal semen. Ginekol-pol. 1994;65(2):71-74.
3. Umeora O., Mbazor J., Okpere E.E. Tubal Factor infertility in Benin City, Nigeria sociodemographics of patients and aetiopathogenic factors. Trop Doct. 2007; 37(2):92-4.
4. Orhue A and Aziken M. (2008). Experience with a comprehensive university hospital based infertility program in Nigeria. Int J Gynaecol Obstet; 101:11-5.
5. Giwa-Osagie O. Nigeria has twelve million infertile persons. Pharma News. 2003; 25 (7):48-49.
6. Benoff S., Jacob A., Hurley I. Male infertility and environmental exposure to lead and cadmium. Hum. Reprod. 6 107-6121.
7. Jurasović J., Cvitković P., Pizent A., et al. Semen quality and reproductive endocrine function with regard to blood cadmium in Croatian male subjects. Biometals. 2004 17:735-743.
8. Telisman S., Colak B., Pizent A. Reproductive toxicity of low-level lead exposure in men. Environ Res. 2007;105:256-266.
9. Hernández-Ochoa., García-Vargas., López-Carrillo L., et al. Low lead environmental

- exposure alters semen quality and sperm chromatin condensation in northern Mexico. *ReprodToxicol.* 2005; 20:221.
10. Bancroft, John, Stevens, et al. Theory and practice of histological techniques. 4th ed. New York: Churchill Livingstone; 1996.
11. Keel B.A, Webster B.W. CRC Handbook of the Laboratory Diagnosis and Treatment of Infertility, Boca Raton: CRC Press Incorporation; 1990.
12. Yan J., Agresti M., Bruce T., Yan Y., Granlund A., Matloub H., (2007). Effects of cellular phone emissions on sperm motility in rats. *Fertil. Steril.* 88: 957–964.
13. Atessahin A.I., Karahan G., Turk S., et al. Protective role of lycopene on cisplatin induced changes in sperm characteristics, testicular damage and oxidative stress in rats. *Repro. Toxicol.* 2006; 21: 42-47.
14. Mustafa H.N. Potential alleviation of *Chlorella vulgaris* and *Zingiberofficinale* on lead induced testicular toxicity: an ultra-structural study. *J. Folia Biological (Krakow)*. 2015;63(4): 269-278.
15. Assi M.A., Hczmee M.N., Haron A.W., et al. The detrimental effects of lead on human and animal health. *Veterinary world.* 2016; 9 (6): 660-671.
16. Acharya U., Acharya S., Mishra M. Lead acetate induced cytotoxicity in male germinal cells of Swiss mice. *Ind Health.* 2003; 41:291-294.
17. Ahmad I., Sabir M., Yasin K. Study of the effects of lead poisoning on the testes in albino rats. *Pak J Med Res.* 2003; 42:256-262.
18. Renner R. Exposure on tap: drinking water as an over looked source of lead. *Environ. Health Prospect.* 2010; 118 (2): A68-A72.
19. Jensen T., Bonde J., Joffe M. The influence of occupational exposure on male reproductive function. *Occup Med.* 2006; 56:544-53.
20. Ali S.A., Al-Derawi K.H., Abd Ali Al monsour N. Testicular toxic effect of lead acetate on adult male rats and the potential protective role of alcoholic extract of ginseng (histological, histomorphometrical and physiological). *Scientific Journal of Medical Research.* 2018; 2(6): 87-92.
21. Pant N., Upadhyay G., Pandey S., et al. Lead and cadmium concentration in the seminal plasma of men in the general population: correlation with sperm quality. *ReprodToxicol.* 2003;17:447-450.
22. Mangelsdorf I., Buschmann J., Orthen B. Some aspects relating to the evaluation of the effects of chemicals on male fertility. *Regul Toxicol Pharmacol.* 2003; 37:356-369.
23. Gurer H., Ercal N. Can antioxidants be beneficial in the treatment of lead poisoning? *Free Radical Biol Med.* 2000; 29: 927-945.
24. Hsu J. Lead toxicity related to glutathione metabolism. *J Nutr.* 1981; 111: 26-33.
25. Batra N., Nehru B., Bansal M. Influence of lead and zinc on rat male reproduction at biochemical and histopathological levels'. *J Applied Toxicol.* 2001; 21:507-512.

