

Molluscum at an Unusual Site: A nipple involving Areolar lesion Mimicking Polythelia with Sebaceous Cyst

Saqib Ahmed, Sheenam Azad, Anshuman Dwivedi

Received on: 02-02-2026

Published on: 30-04-2026

ABSTRACT

Molluscum contagiosum (MC) is a cutaneous benign infection. DNA poxvirus is known to be its causative agent. It usually affects the exposed areas of the human body. Involvement of the nipple areolar complex (NAC) is exceedingly rare and may sometimes mimic benign or malignant adnexal lesions, posing a diagnostic challenge. We report a case of MC presenting nodular lesions over the NAC clinically suspected as polythelia with sebaceous cyst. Histopathological examination confirmed the diagnosis. Such atypical presentations can lead to diagnostic dilemmas, and possible differential of molluscum should always be kept in mind.

KEYWORDS: Molluscum contagiosum, nipple areola complex, histopathology

Era's Journal of Medical Research. 13(1);2026 [doi: 10.24041/ejmr.2026.18]

INTRODUCTION

Molluscum contagiosum is caused by a double stranded DNA virus.¹ It presents as multiple, tiny dome shaped pearly papules along with central depression and involves the exposed areas predominantly including the extremities, face, trunk and genital region.² However, involvement of the nipple area is extremely uncommon and limited literature. Such atypical presentations may clinically mimic benign adnexal tumors, accessory nipple (polythelia), sebaceous cysts, or even malignant lesions, thereby creating diagnostic dilemmas.³ In such cases microscopic examination is helpful in the final diagnosis removing the diagnostic dilemma.

Case Presentation

A young female with an age of 29-years experienced pruritis near the nipple, right breast for a period of one month. There was no history of discharge, trauma, or systemic symptoms.

On clinical examination, two small, non-tender nodules were noted around the right nipple without overlying skin changes, or axillary lymphadenopathy. Ultrasonography revealed two well-defined hypoechoic cutaneous lesions within the areolar region, with no internal vascularity or extension into the underlying breast parenchyma. A provisional clinical diagnosis of polythelia with sebaceous cyst was considered. The lesions were excised and submitted for histopathological evaluation. On gross examination there were two grey-white, unoriented soft tissue fragments measuring: 0.8 × 0.5 × 0.2 cm and 0.7 × 0.4 × 0.3 cm. On microscopic examination sections revealed skin lined by stratified squamous epithelium showing marked acanthosis lobulated endophytic epidermal hyperplasia forming cup-shaped invaginations extending into the dermis (Figure 1).

Department of Pathology, Shri Guru Ram Rai Institute of Medical & Health Sciences, Dehradun, Uttarakhand, India.

Corresponding Author: Saqib Ahmad

Email: saqibahmed.mail@gmail.com

How to cite: Ahmed S, Azad S, Dwivedi A. Molluscum at an Unusual Site: A nipple involving Areolar lesion Mimicking Polythelia with Sebaceous Cyst. *Era J Med Res.* 2026;13(1):95-96.

Keratinocytes exhibited large intracytoplasmic inclusion bodies, eosinophilic in appearance (Henderson Patterson bodies), which displaced the nucleus peripherally (Figure 2a, 2b). The underlying dermis showed moderate chronic inflammatory infiltrate. No evidence of dysplasia or malignancy was identified. A final diagnosis of Molluscum contagiosum involving nipple-areolar complex.

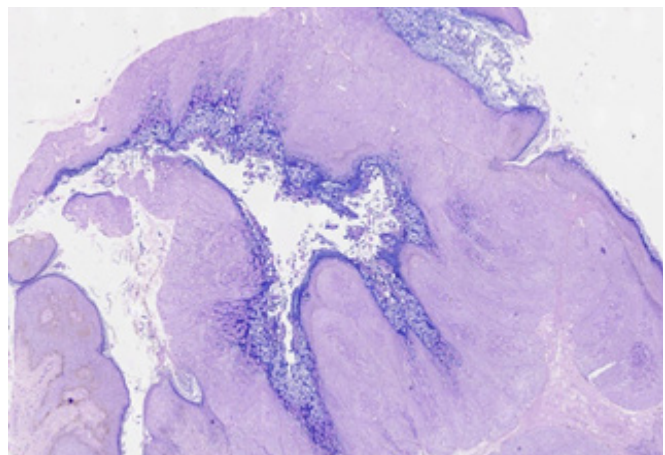


Figure 1: Photomicrograph showing lobulated endophytic epidermal hyperplasia forming a downward invagination extending into the dermis (H&E, X10).

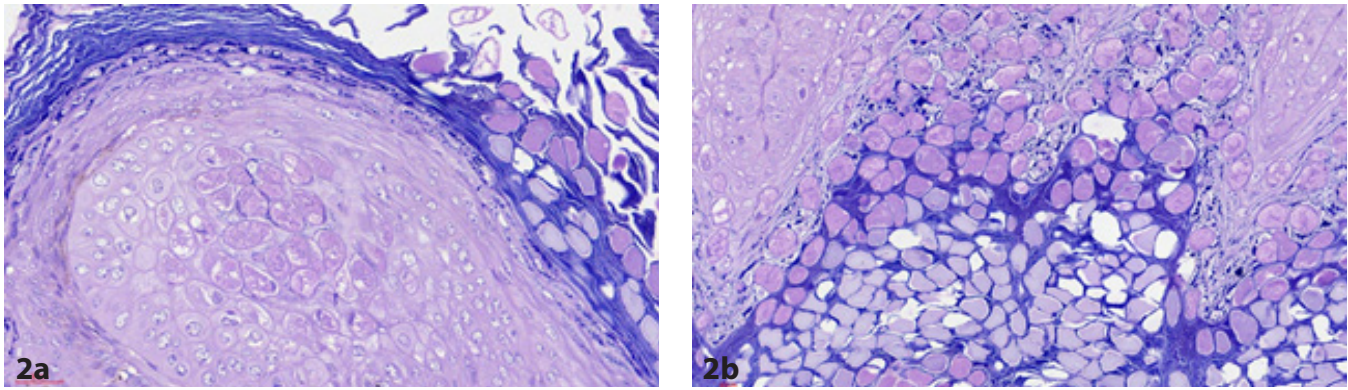


Figure 2a, 2b: Photomicrograph showing Henderson–Patterson bodies (H&E, X100).

DISCUSSION

MC is caused by viral replication within keratinocytes, leading to accumulation of virions and formation of characteristic intracytoplasmic inclusion bodies.⁴ Transmission occurs via direct contact, autoinoculation, or fomites. Although MC commonly involves exposed skin in children and genital areas in adults, involvement of the NAC is rare. Such atypical presentations may clinically mimic polythelia, sebaceous cyst, epidermal inclusion cyst, Paget's disease of the nipple and Other adnexal tumors. Rare cases of MC involving the NAC have been documented in the literature. Al Hamoud *et al.* reported a similar presentation in a young adult, while Al-Murieh *et al.* described involvement of the nipple in a toddler.^{5,6} Histopathologically, MC is characterized by Cup-shaped epidermal invaginations, lobulated epidermal hyperplasia, presence of Henderson–Patterson bodies. These features are diagnostic and help distinguish MC from its mimics. For instance: Paget's disease shows atypical CK7-positive Paget cells without viral inclusions, Sebaceous cysts lack viral cytopathic changes. Recognition of these features is critical to prevent misdiagnosis and overtreatment.

CONCLUSION

Molluscum contagiosum involving the nipple area is an uncommon entity that may clinically mimic benign and malignant lesions. Histopathological examination demonstrating characteristic Henderson Patterson bodies is the mainstay for definite diagnosis. Awareness of this rare presentation is essential for accurate diagnosis and appropriate patient management, thereby avoiding unnecessary aggressive interventions.

REFERENCES

1. Chen X, Anstey AV, Bugert JJ. Molluscum contagiosum virus infection. *Lancet Infect Dis.* 2013;13(10):877–888.
2. Sterling JC. Virus infections. In: Griffiths C, Barker J, Bleiker T, Chalmers R, Creamer D, editors. *Rook's Textbook of Dermatology.* 9th ed. Oxford: Wiley-Blackwell; 2016. p. 25.1–25.44.
3. Brown J, Janniger CK, Schwartz RA, Silverberg NB. Childhood molluscum contagiosum. *Int J Dermatol.* 2006;45(2):93–99.
4. Dohil MA, Lin P, Lee J, Lucky AW, Paller AS, Eichenfield LF. The epidemiology of molluscum contagiosum in children. *J Am Acad Dermatol.* 2006;54(1):47–54.
5. Al Hamoudi WK, Al Mulla A, Al Ateeq M. Molluscum contagiosum of the nipple: an unusual presentation. *Case Rep Dermatol.* 2012;4(3):256–260.
6. Al-Murieh M, Al-Shehri A. Molluscum contagiosum involving the nipple in a child: a rare presentation. *Pediatr Dermatol.* 2010;27(3):317–318.

Orcid ID:

Saqib Ahmed - <https://orcid.org/0000-0003-4096-2725>

Sheenam Azad - <https://orcid.org/0000-0002-7535-4976>

Anshuman Dwivedi - <https://orcid.org/0000-0002-0505-1494>