

BRENNER TUMOR OF OVARY - A RARE CASE REPORT

Swankita Raj, Geeta Yadav, Nirupama Lal, Kumkum Rani Srivastava, Uma Gupta

Department of Obstetrics and Gynecology

Era's Lucknow Medical College and Hospital, Era University, Sarfarazganj, Lucknow, U.P., India-226003.

Received on : 06-10-2023

Accepted on : 26-12-2023

ABSTRACT

Brenner tumours of the ovary are typically discovered incidentally, and they are a rare occurrence primarily affecting women in their fifth to sixth decade of life. These tumours are classified as transitional cell tumours of the ovary, encompassing benign, borderline, and malignant Brenner tumours, as well as transitional cell carcinoma. Unfortunately, there is no dependable tumour marker for diagnosing Brenner tumours, and they cannot be accurately identified through imaging studies. In this case report, we present an unusual instance of a 50-year-old postmenopausal woman who experienced abdominal pain and detected a lump in her abdomen. As a result, she underwent a Total abdominal hysterectomy with bilateral salpingo-oophorectomy the postoperative histological analysis confirmed the presence of a tumour in the right ovary.

KEYWORDS: Brenner tumour, Ovarian neoplasm, Histopathology.

INTRODUCTION

Ovarian cancer, ranked as the seventh most prevalent cancer worldwide, presents itself in various ways and often goes undetected until it reaches a significant size. In terms of global occurrence, India holds the unfortunate position of being the second-highest country affected by ovarian cancer (1). The burden of ovarian lesions in the field of gynaecology is significant, primarily due to the tumour's location and its tendency to remain asymptomatic for prolonged periods. The World Health Organization's histological classification of ovarian tumours groups them based on the most likely tissue of origin. These categories include surface epithelial tumours, accounting for about 65% of cases, germ cell tumours at 15%, sex cord-stromal tumours at 10%, metastatic tumours at 5%, and other miscellaneous types.

Brenner tumours are an uncommon type of epithelial ovarian tumour, specifically categorized as a rare subtype of Transitional cell Tumour of the ovary. They were initially identified and named by Fritz Brenner in 1907 and account for only 2-3% of all ovarian tumours (2,3). As per the World Health Organisation (WHO) classification, Brenner tumours can be further classified based on their histopathological pattern into benign, borderline, or malignant, and they are also considered transitional cell carcinomas. These tumours typically appear unilaterally, with bilateral cases comprising only 5-7% of occurrences, and they tend to affect postmenopausal women more frequently

(4). In terms of diagnosis, ultrasound (USG) and computed tomography (CT) have limited sensitivity due to their nonspecific appearance. Therefore, microscopic pathological examination is essential, which reveals an abundance of dense fibrous stroma with epithelial nests of transitional cells displaying coffee bean-shaped nuclei, resembling those found in the lining of the urinary bladder.

We present a case of a 50-year-old female who complained of abdominal pain and was diagnosed with benign Brenner tumours upon histopathological analysis. Our aim in sharing this case is to highlight the rarity of Brenner tumours and to document the typical features observed in benign Brenner tumours.

CASE REPORT

Fifty-year multiparous female came in Gynae OPD complaint of mild lower abdominal pain off and on for 3 months. In her past history she is K/C/O hypertension and hypothyroidism from last 12 year and she is on medication. In examination her vitals are within normal range, and general examination within normal limit. Her cardiovascular, respiratory and central nervous system was normal. On per abdomen examination a midline firm mass felt of approx. 16 weeks size at suprapubic region which was mobile and nontender. Local examination no abnormality detected, per speculum examination shows healthy cervix and vagina. Per vaginal examination finding was cervix forward, uterus normal size, Retroverted, in right fornices mass of approximately 10x8 cm felt which was

Address for correspondence

Dr. Swankita Raj

Department of Obstetrics and Gynecology
Era's Lucknow Medical College &
Hospital, Era University, Lucknow-226003.
Email: swankitaraj@gmail.com
Contact no: +91-9794237821

firm mobile and nontender. The USG finding showed a 99x96x101 mm right ovarian lesion suggestive of Dermoid cyst. CE MRI findings was large size well defined homogeneously T1/T2 hypointense lesion (7.6x9.6x10.1cm) in Rt adnexa suggestive of right ovarian fibroma. Tumor markers CA 125- 7.7U/ml, CEA-2.05 ng/ml, b HCG-0.31 IU/L, AFP-1.91 ng/ml.

Patient taken for exploratory laparotomy, while operating, a large firm mass arising from right ovary of approx. 10x8x8cm with right fallopian attached to it was found. Uterus, left ovary and fallopian tubes found healthy. No per op finding suggestive of malignancy found. Peritoneal wash sends for cytology. Decision of TAH with BSO taken and performed. Grossly the tumor was 10.5x 8 x 6 cm sizes with well encapsulated, solid, bosselated gray white, with rubbery consistency. Cut surface showed grayish white to yellowish solid areas. Histopathology report- section from right ovarian tissue suggestive of Brenner Tumour. Left ovary, uterus and both tubes were unremarkable.

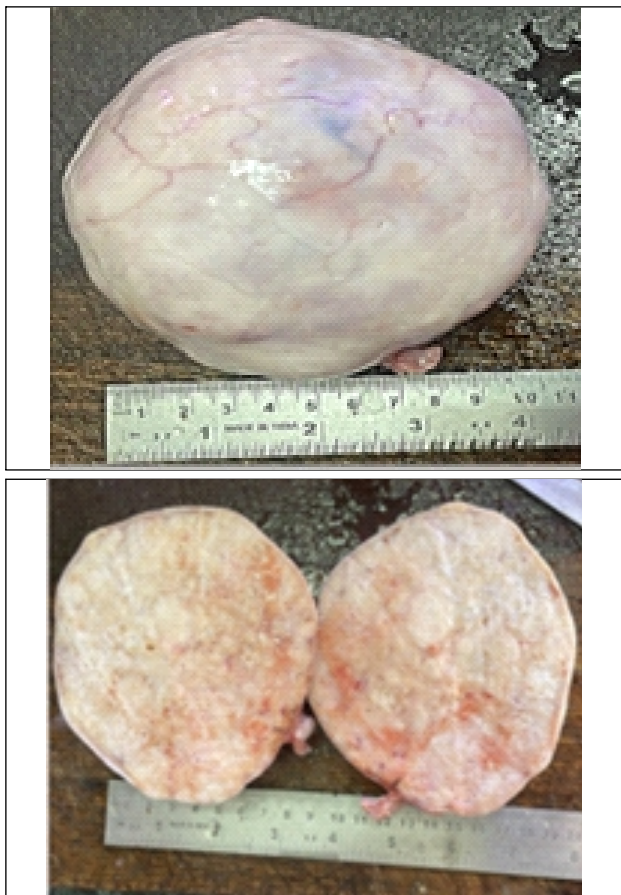

Fig. 1. Gross Appearance of Tumor-asingle well Encapsulated, Solid, Globular, Bosselated Gray White Soft Tissue with Rubbery Consistency Measures 10.5X8X6CM cut surface shows Grayish White to Yellow Solid areas.

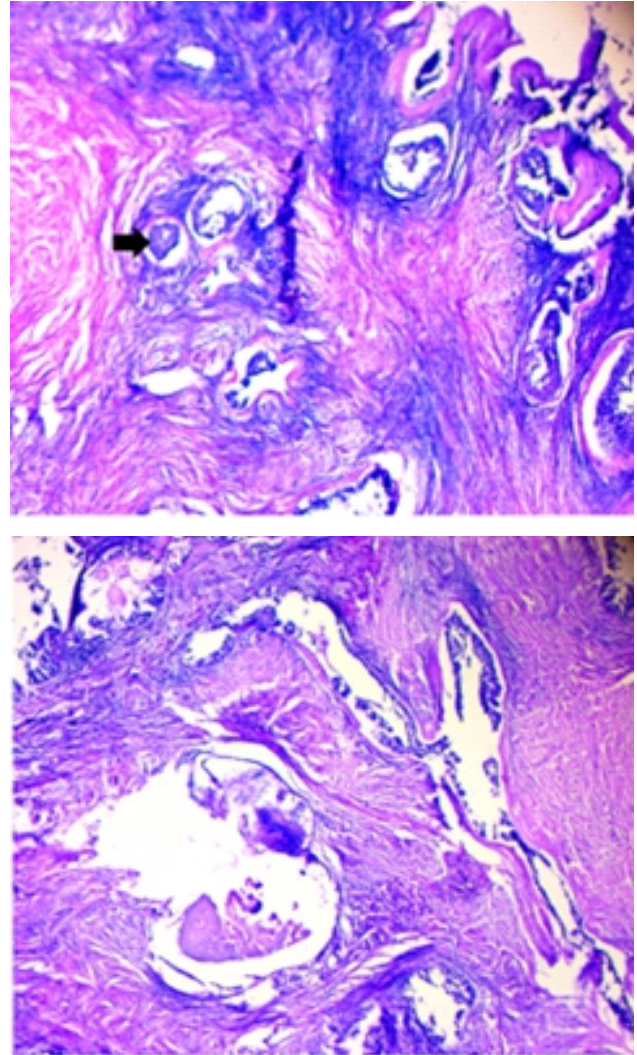


Fig. 2: Section from Right Ovarian Tissue shows a Tumor composed of small oval to Irregular nests of Bland transitional Epithelium in a Storiform Ovarian Stroma. The transitional epithelium exhibit oval Nuclei with prominent cell borders and eosinophilic cytoplasm. Few of the nests show cystic spaces lined by transitional epithelium containing eosinophilic secretions.

During post-op period patient was doing well and discharged on 7th postoperative day with follow-up advice.

DISCUSSION

Brenner tumour is a less common subtype of transitional epithelial tumours found in the ovaries. The majority of these tumours are benign, and malignant forms are quite rare (5). Typically, Brenner Tumours are known to occur most frequently in women during their fifth to sixth decade of life, with around 71% of patients being above 40 years old. In our case, the Tumour presented at the age of 50 years, which aligns with this age trend.

A case series conducted by Gezginc et al (6) demonstrated that the age range at which Brenner Tumours were diagnosed varied from 43 to 79 years. Another case series by Lin et al (7) featured the youngest patient diagnosed at 41 years old, and Han et al (8) presented a case with the youngest patient diagnosed at 37 years old. These findings indicate that although Brenner Tumours usually appear in older age groups, they can occasionally affect younger individuals as well.

Benign Brenner tumour is typically discovered incidentally during pathological examinations. In the majority of cases, it is found to be unilateral, with bilateral occurrences being rare, observed only in about 5-7% of cases. Many cases are asymptomatic, but when symptoms do occur, they often include abdominal distension, abdominal pain, a palpable pelvic mass, pelvic pain, and vaginal bleeding. In our patient's case, she presented with lower abdominal pain persisting for 3 months.

Another non-specific symptom was reported by Baizabal-Carvello et al. (2010), where their patient initially presented with symptoms of intracranial hypertension resulting from dural metastasis (9), ovarian tumours effects can manifest in various ways beyond the typical gynecological symptoms.

Both ultrasound (USG) and computed tomography (CT) are lesser sensitive methods for diagnosing Brenner Tumours due to their nonspecific appearance in imaging studies. These tumours often resemble with another benign tumour like fibrothecoma, fibroma, and long pedicle leiomyoma (10). While sonography can help differentiate solid from cystic masses, it has limited effectiveness in detecting small tumours. In our case, the USG findings indicated a 99x96x101 mm right ovarian lesion that was suggestive of a Dermoid cyst. MRI findings commonly associated with Brenner tumours include solid hypo intense lesions on T2-weighted images, as well as solid components with higher intensity on T1-weighted images (11). In our case, contrast-enhanced MRI revealed a large, well-defined, homogeneously hypointense lesion (7.6x9.6x10.1 cm) in the right adnexa, which was suggestive of a right ovarian fibroma. These imaging challenges demonstrate the difficulty in differentiating Brenner Tumours from other ovarian masses using standard imaging techniques. Histopathological examination remains the most reliable method for accurate diagnosis.

While there are no specific tumour markers exclusively identified for Brenner Tumours (BT) to aid in their diagnosis, CA-125 can be utilized to differentiate between benign and malignant cases and also to monitor potential recurrence in malignant instances during follow-up (12). According to a study conducted

by Yüksel D et al (13), they observed that CA-125 levels were greater than 35 IU/mL in 38% of malignant Brenner Tumours and 28% of benign Brenner Tumours.

Microscopically, benign Brenner Tumours (BT) are distinguished by sharply demarcated epithelial nests set within a dense fibrous stroma. These epithelial cells exhibit characteristics of transitional cells, displaying a uniform stratified cells with well-defined cell borders. The nuclei are oval-shaped and often reveal longitudinal nuclear grooves, giving them a distinct coffee-bean appearance, and may also feature small nucleoli. In comparison, malignant Brenner Tumours (MBT) show more angulated epithelial nests than those observed in benign BT. These histological features play a crucial role in diagnosing and differentiating Brenner Tumours from other ovarian neoplasms and are essential for the accurate classification of the tumour as benign or malignant.

Surgical resection of the tumour mass is both diagnostic and curative for Brenner Tumours. Similar to other ovarian epithelial tumours, surgical procedure options include hysterectomy, salpingo-oophorectomy, omentectomy, and appendectomy, with or without pelvic and para-aortic lymphadenectomy. The choice of specific surgical procedures depends on factors such as the size and extent of the tumour, whether it is unilateral or bilateral, and the presence of any signs of malignancy. Surgical resection is often the primary treatment for Brenner Tumours, and it is typically curative for benign and some borderline cases. For malignant Brenner Tumours or cases with advanced disease, additional treatments such as chemotherapy or radiation therapy may be considered in conjunction with surgery.

CONCLUSION

In summary, due to its rarity and the limitations of radiological investigations, histopathological examination remains the most reliable and definitive approach for diagnosing Benign Brenner tumours, regardless of their size.

REFERENCES

1. SEER*Stat Database: NAACCR Incidence Data - CiNA Analytic File, 1995-2014, for Expanded Races, Custom File with County, ACS Facts and Figures projection Project December 2016.
2. Speert H. Obstetrical-gynaecological eponyms: Fritz Brenner and Brenner tumours of the ovary. *Cancer*. 1956; 9(2): 217-221.
3. Longacre TA, Gilks CB, Nucci MR, et al. Surface epithelial-stromal tumours of the ovary. London: Churchill Livingstone Elsevier; 2009.
4. Hemalatha AL, Konanahalli P. Bilateral

- malignant Brenner tumourof ovary. J Obstet Gynecol India. 2005; 55(1): 81-82.
5. Seidman JD, Cho KR, Ronnett BM, et al. Surface Epithelial Tumours of the Ovary. 6th ed. New York: Springer; 2011.
 6. Gezginç K, Karatayli R, Yazici F, et al. Malignant Brenner tumour of the ovary: Analysis of 13 cases. Int J Clin Oncol. 2012; 17(4): 324-329
 7. Lin DI, Killian JK, Venstrom JM, et al. Recurrent urothelial carcinoma-like FGFR3 genomic alterations in malignant Brenner tumours of the ovary. Mod Pathol. 2021; 34(5): 983-993
 8. Han J-H, Kim D-Y, Lee S-W, et al. Intensive systemic chemotherapy is effective against recurrent malignant Brenner tumour of the ovary: An analysis of 10 cases within a single center. Taiwan J Obstet Gynecol. 2015; 54(2): 178-182.
 9. Baizabal-Carvallo JF, Barragán-Campos HM, Alonso-Juárez M, et al. Dural metastases as a presentation of a Brenner tumour. J Clin Neurosci. 2010; 17(4): 524-526
 10. Athey PA, Siegel MF. Sonographic features of Brenner tumour of the ovary. J Ultrasound Med. 1987; 6(7): 367-372.
 11. Takahama J, Ascher SM, Hirohashi S, et al. Borderline Brenner tumour of the ovary: MRI findings. Abdom Imaging. 2004; 29: 528-530.
 12. Lang SM, Mills AM, Cantrel LA. Malignant brenner tumour of the ovary: review and case report. Gynecol Oncol Rep 2017; 22: 26-31
 13. Yüksel D, Kılıç C, Çakır C, et al. Brenner tumours of the ovary: clinical features and outcomes in a single-centre cohort. J Turk Ger Gynecol Assoc. 2022; 23(1): 22-27.



Orcid ID:

Swankita Raj - <https://orcid.org/0009-0009-8741-4671>

Geeta Yadav - <https://orcid.org/0000-0001-7605-4847>

Nirupama Lal - <https://orcid.org/0000-0001-9615-5426>

Kumkum Rani Srivastava - <https://orcid.org/0009-0001-4941-0401>

Uma Gupta - <https://orcid.org/0000-0002-6952-457X>

How to cite this article:

Raj S., Yadav G., Lal N., Srivastava K.R., Gupta U. Brenner Tumor of Ovary - A Rare Case Report. Era J. Med. Res. 2023; 10(2): 122-125.

Licencing Information

Attribution-ShareAlike 2.0 Generic (CC BY-SA 2.0) Derived from the licencing format of creative commons & creative commons may be contacted at <https://creativecommons.org/> for further details.