EJMR
ERA'S JOURNAL OF MEDICAL RESEARCH
p-ISSN: 2348-9839, e-ISSN: 2394-5222 | www.ejmr.org
Volume 13 Issue 2
CASE REPORT

A Case Series on Surgical Challenges and Psychiatric Dimensions of Foreign Bodies in Urology

Mohammad Shazib Faridi, Abdul Qadir Boringwala, Kartik Sridhar, Devesh Bhatia, Neel Swaminarayan, Prashant Garg

Received on: XX Published on: XX

ABSTRACT

Background: Genitourinary foreign bodies are one of the less common urological emergencies that are increasingly noted in recent times. Presentations include urethral sounding, penile ring entrapment and complex rectovesical injuries. Embarrassment, often the cause of delayed presentation, increases the risk of complications. This is a series of five cases demonstrating the clinical spectrum and the related surgical and psychiatric concerns.

Methods: Five patients who are presented with genitourinary foreign bodies to our center are presented. Clinical features, radiological findings, management approaches, and outcomes were studied.

Results: The cases included an adolescent who self-inserted insertion a vinyl tube into the bladder, acute penile ring incarceration, penile strangulation associated with paraphimosis, and a rectal foreign body leading to complex entero-vesical and entero-enteric fistula, resulting in mortality. Management varied from open cystostomy to emergency decompression and multi-organ reconstruction.

Conclusion: Genitourinary foreign bodies present with varying levels of severity, from reversible edema to life-threatening complications. Early intervention, tailored surgical plans, and psychiatric assessment are key to reducing complications.

KEYWORDS: *Emergencies, Foreign body, Penile diseases, Urinary bladder, Urinary fistula.*

Era's Journal of Medical Research. 13(2);2026 [doi: 10.24041/ejmr.2026.#]

INTRODUCTION

Foreign bodies in the lower genitourinary tract are uncommon yet not rare in urological practice. The majority of presentations are urethral self-insertion for erotic pleasure, with few due to underlying psychiatric problems.[1–4]

Penile ring entrapment is a urological emergency where inappropriate usage of constriction rings, used to maintain an erection, causes ischemia or even tissue loss of the organ. Gangrene might occur due to venous congestion, ischemia, and is an end presentation of the spectrum.[5,6] No universal protocol for dealing with this condition exists even as different grades of constriction require different therapeutic approaches.[7] An unusual case, rectal foreign body may lead to a potentially fatal condition if perforates the bowel and causes a fistula involving the bladder.[8]

We present five cases within over nine months illustrating spectrum of disease, ranging from salvageable pathology to catastrophic outcome, with emphasis on surgical decision-making and psychiatric considerations.

CASE SERIES

Case 1

A 16-year-old boy presented with intermittent lower abdominal pain and hematuria for 1 year. He also reported occasional passage of worms in the urine for 8 months, for which he had already received multiple antiparasitic medications from local practitioners without improvement. There was no similar history in his family or locality. The physical examination and routine blood tests were normal. The urine culture was positive for *Escherichia coli*, which was treated accordingly. Ultrasound (USG) abdomen showed multiple tubular structures within the urinary bladder, most likely parasites.

Cystoscopy revealed an encrusted, convoluted, knotted vinyl tube in the urinary bladder (Figure 1A). Endoscopic retrieval failed due to multiple knots, and open cystostomy was performed to retrieve the tube (Figure 1B). On straightening, the tube measured approximately 150 cm. The patient later disclosed insertion of the tube into the urethra for erotic pleasure and believed it had passed spontaneously at the time. The post-operative course was uneventful, and the patient was discharged on post-

Department of Urology, Dr Baba Saheb Ambedkar Medical College & Hospital, Rohini, Delhi, India.

Corresponding Author: Mohammad Shazib Faridi

Email: drshazibfaridi@gmail.com

How to cite: Faridi MS, Boringwala AQ, Sridhar K, Bhatia D, Swaminarayan N, Garg P. A Case Series on Surgical Challenges and Psychiatric Dimensions of Foreign Bodies in Urology. Era J Med Res. 2026;13(2):0-0.

Attribution-ShareAlike 4.0 International (CC BY-SA 4.0) Derived from the licencing format of creative commons & creative commons may be contacted at (https://creativecommons.org/licenses/by-sa/4.0/deed.en) for further details.

AHEAD OF PRINT..... AHEAD OF PRINT..... AHEAD OF PRINT..... AHEAD OF PRINT..... AHEAD OF PRINT..... AHEAD OF PRINT.....

operative day 5. The psychiatric assessment showed no abnormalities. Follow-up was unremarkable.

Case-2

A 42-year-old male presented to the emergency department with severe penile pain and progressive swelling of 9 hours duration. The patient reported routine use of metallic penile rings before sexual intercourse to maintain erection. On this occasion, however, he was unable to remove the ring after intercourse, Over the next several hours, progressive distal penile swelling and escalating pain developed. Local examination revealed a thick metallic ring constricting the base of penis. The penis distal to the ring was markedly edematous, tense, congested and tender (Figure 2A). There was no skin ulceration, necrosis, or urethral discharge.

The patient was shifted for urgent decompression under regional anesthesia. Initial removal attempts included lubrication-assisted manual compression and attempts to slide the ring distally. Then an orthopedic plier was used to cut the ring; however, these maneuvers were unsuccessful. Subsequently, attention was then directed toward decompression of the distal edema. Multiple punctures were made over the glans and distal prepuce using a wide-bore needle. Manual compression with glycerin was applied circumferentially to evacuate edematous fluid and reduce tissue tension. Gradual reduction in penile circumference was achieved over several minutes. This allowed the metallic ring to be carefully slid off the penile shaft without causing additional tissue injury (Figure 2B).

Penile detumescence occurred promptly after release of the constriction without any evidence of ischemia, necrosis, or urethral injury. The puncture wounds were dressed, and prophylactic antibiotics were administered. The Edema gradually subsided over the next 3 days. He was discharged with advice regarding wound care and counseled about the risks of constrictive devices. Psychiatric referral was advised; however, the patient lost to follow-up.

Case-3

A 60-year-old male presented to the urology OPD with a foreign body constricting the penis for approximately 12 days. Although he acknowledged having performed similar acts previously, he did not clearly state the motive behind the behavior. Even though no psychiatric diagnosis could be made, concealment and embarrassment lead to delayed presentations. The patient reported progressive penile swelling associated with pain started shortly after ring placement. At the presentation, he denied any difficulty in urination.

On examination, he was hemodynamically stable with a rigid rectangular brass ring tightly impacted at the coronal sulcus (Figure 3A). The distal penile shaft and glans were markedly edematous, tense, and erythematous with superficial skin ulceration at the site of constriction. The prepuce was retracted behind the glans, and paraphimosis was present with formation of a constriction band at the site of impaction. The glans appeared congested but viable, with preserved sensation. There were no overt signs of gangrene, black discoloration, or necrosis.

The patient was taken up for emergency surgical intervention under regional anesthesia. A urethral catheter was inserted without difficulty to ensure unobstructed urinary drainage and monitor for possible urethral compromise secondary to prolonged edema. Careful protection of the underlying penile tissue was ensured using a thin metal guard interposed between the ring and skin. The brass ring was divided using a Gigli saw, after an attempt with orthopedic plier was unsuccessful (Figure 3B). Partial reduction of distal penile edema was achieved using glycerin and manual pressure. A dorsal slit procedure was performed to relieve the constricting preputial band and paraphimosis. The penile shaft was inspected thoroughly; Superficial skin abrasions were noted, but there was no full-thickness necrosis or urethral injury. Postoperatively, penile edema gradually subsided over the next 72 hours. The catheter was removed on postoperative day 3 after satisfactory voiding was confirmed. The patient was discharged in stable condition with advice regarding wound care. Psychiatric evaluation was unremarkable with an uneventful follow-up.

Case-4

A 66-year-old male presented with penile pain for 1 month, along with urine leakage from the base of the penis for 8 days. There was no prior similar illness.

On further inquiry, the patient revealed that he had applied a metallic ring at the base of his penis approximately 4 months earlier, on the advice of an unqualified practitioner, believing that it would alleviate his general health issues and chronic cough. The ring had not been removed since the application. The patient delayed seeking medical attention because of embarrassment and social stigma and was eventually brought by family members after the development of foul odor.

On examination, a metallic constricting ring was present at the base of the penis. The distal penile shaft was grossly edematous, tense, and congested, with dusky-to-black discoloration and patchy areas suggestive of gangrene. Distal penile sensation was absent. At the site of construction, there was ulceration with slough formation (Figure 4A). No active urine leakage was noted at the presentation.

The patient was taken for emergency surgical intervention after obtaining informed consent, including the possibility of suprapubic catheterization, partial or total penectomy, and perineal urethrostomy. Intraoperative assessment revealed a partial tear of the proximal penile urethra at the penoscrotal junction and non-viable multiple gangrenous patches distal to the construction site.

AHEAD OF PRINT..... AHEAD OF PRINT..... AHEAD OF PRINT..... AHEAD OF PRINT..... AHEAD OF PRINT..... AHEAD OF PRINT.....

Because of the extent of ischemic damage, total penectomy was performed. The penile shaft, along with the constricting ring, was excised (Figure 4B, 4C). The corpora cavernosa was transfixed, and a suprapubic catheter (SPC) was placed, urethral stump and wound was closed in layers.

The postoperative period was uneventful. The patient was discharged on POD 3 with SPC in situ. Histopathology of the specimen revealed acute necrosis of the penis parenchyma with thrombosed blood vessels and acute inflammation in the urethra, findings suggestive with gangrenous penis. He was advised to undergo perineal urethrostomy and psychiatric evaluation; however, he did not follow-up.

Case-5

A 33-year-old male presented to the emergency department with suprapubic pain of 8 hours' duration and pneumaturia for 7 days. The patient reported insertion of a foreign body per rectum several days earlier but denied repetitive behavior or providing detailed explanation of the act. There was no known history of psychiatric illness, substance abuse, or prior to abdominal surgery. On arrival, he was hemodynamically stable. On examination of a firm, mass palpable in the suprapubic region extending up to the umbilicus. The rest of the abdomen was soft and non-tender without any signs of guarding or rigidity. On digital rectal examination, the anal sphincter was laxed, and the rectum was spacious to accommodate 4 fingers. The lower end of a hard foreign body was palpable at the examining finger. There was no active rectal bleeding.

Abdominal x-ray revealed an inverted glass-shaped object in the pelvis (Figure 5A). Urethral catheterization was performed, yielding approximately 50 mL of blood-tinged urine.

Emergency exploratory laparotomy was performed through an infra-umbilical midline incision. Dense inflammatory adhesions were encountered in the pelvis. The foreign body was palpable in the sigmoid colon, and enterotomy was made over the antimesenteric border to retrieval it. An inverted steel glass was removed intact (Figure 5B).

Further, exploration revealed a complex fistulous communication involving the posterior wall and dome of the urinary bladder, the distal sigmoid colon, and a loop of ileum approximately 5 to 7 cm proximal to the ileocecal junction. The fistulous tracts appeared to result from chronic pressure necrosis and inflammatory erosion. The surrounding tissues were edematous and inflamed, although no gross fecal peritonitis was present. The remaining small and large bowels appeared normal. A staged reconstructive approach was undertaken. The fistulous tracts were meticulously dissected and divided. The bladder was repaired in layers, and anterior cystostomy was made as urinary diversion. Bilateral ureteric catheterization was performed, and the ureteric catheters were exteriorized through the anterior abdominal wall to safeguard ureteral patency and facilitate postoperative monitoring. A suprapubic catheter was placed.

The involved ileal segment was exteriorized as a loop of ileostomy to divert fecal stream and protect distal repairs. The diseased sigmoid segment was divided, and an end sigmoid colostomy with distal mucus fistula was fashioned. Because of anticipated postoperative edema, contamination risk, and the magnitude of reconstruction, a laparostomy with Bogota bag was performed to allow planned re-exploration. Drains were placed in the space of retzius and pelvic regions.

The patient was transferred on ventilatory support to the intensive care unit. He required postoperative vasopressor support due to persistent hypotension, likely secondary to systemic inflammatory response syndrome. Broad-spectrum antibiotics were administered. Urine output was approximately 1 liter per day throughout the post- operative period.

On postoperative day (POD) 3, the patient returned to the operating room for formal abdominal closure. At that time, bowel viability was reassessed and appeared satisfactory. The abdomen was closed without tension. Gradual clinical improvement was observed over the next few days. The patient was successfully extubated on POD 6 and maintained on oxygen via a non-rebreathing mask.

Although the patient initially showed signs of recovery after staged reconstruction, he remained at risk due to ongoing systemic inflammatory response. He subsequently developed septic shock, eventually leading to sudden hemodynamic collapse on POD 6. Despite immediate cardiopulmonary resuscitation and advanced life support, the patient could not be revived.

DISCUSSION

Foreign bodies in genitourinary tract represent a diverse group of urological emergencies, ranging from benign intravesical pathology to potentially pelvic sepsis and even death. Traditionally regarded as a rare entity, contemporary evidences suggest increment in emergency presentations of genital foreign body injuries, mainly in adult males. This can be explained by evolving sexual practices, better reporting, and overall social changes rather than a true rise in incidence of the disease.

Intravesical foreign bodies inserted via urethral sounding is one of the most common lower urinary tract insertions, and is usually done for autoerotic stimulation, sexual curiosity and it does not necessarily imply the presence of formal psychiatric pathology.[1,4] All patients presenting with urethral sounding were adult males with no psychiatric illness documented described in the case series.[4] Flexible foreign bodies like wires and tubes are particularly at risk

EDITED

AHEAD OF PRINT.....

of knotting due to bladder detrusor muscle contractions.[1,9] After knotting occurs, endoscopic removal can be technically dangerous and can lead to urethral and bladder injury. In such circumstances, timely transition to open cystostomy is prudent and is not to be considered a failure.[9] Similar to our adolescent patient, where an intravesical foreign body was removed by open cystostomy due to complex knots, reinforcing that patient safety is the utmost priority over persistence with minimally invasive measures.

Penile strangulation has different pathogenesis characterized by progressive vascular impairment. The constricting device, applied for enhancement of erection, initially occludes venous flow, leading to peripheral congestion and edema. Continuous occlusion also impedes lymphatic drainage, causing increase intracavernosal pressure, further compromising arterial flow and eventually leading to ischemia, necrosis, urethral injury, and even gangrene.[5,6] Campbell *et al.* in a review of 100 cases of penile strangulation emphasized that injury severity is directly proportional to duration of incarceration and the fact that metallic rings accounted for significant proportion of penile injuries with one fourth developing long-term sequelae.[6] Similarly, another study showed that progression to high grade penile injury culminating to penectomy, occurs when the presentation is delayed.[10]

To stratify the degree of injury, Bhat *et al.* divided penile incarceration cases into five grades, although criticized for being incomplete by ignoring corporal ischemia or erectile dysfunction, still remains the single most widely cited stratification.[7] Grades have been enumerated as: Grade I (distal penile edema without penile skin or urethral injury); Grade II (penile skin injury without urethral injury); Grade III (urethral injury without urethral fistula); Grade IV (urethral fistula or division of corpus spongiosum); and Grade V (penile gangrene or amputation). Application of this classification to our cases highlights the time-dependent progression of tissue injury. The case-2 patient presented with isolated distal edema (Grade I injury), early decompression facilitated organ preservation. In contrast, the case-3 patient presented after 12 days with skin abrasion and paraphimosis without urethral injury, consistent with Grade II severity. The grade V injury, which occurred in our case-4, was presented after four months of incarceration, leading to penile gangrene. This extreme presentation has typically ensued as patients avoid evaluation and treatment due to social stigmas, embarrassment and misguided information. From a surgical perspective, Grade V presentation immediately requires a definitive treatment such as total penectomy with planned perineal urethrostomy to curb ascending necrotizing infections and sepsis. Several studies documented that late presentation can result in urethral fistula, necrosis, and gangrene, similar to our series.[10,11] In contrast to grades I and II injury, and extremes such as Grade V injury in our series, the key factor for the good outcome is the duration of incarceration.

The treatment technique is individualized, and depend on the device properties including the material composition and its thickness, the time of entrapment and available resources. Treatment options include various methods like simple lubrication, compression, strings, needle aspiration techniques, bolt cutters, orthopaedic gigli saws, dental micromotors, and industrial tools.[5,12–14] The string technique introduced by Vyas et al may be a simple and helpful technique in tissue preservation in certain patients.[14] Unlikely heavy metal devices require to be cut by special blades under guidance.[12] Dawood *et al.* advocated that rapid, yet controlled removal of the devices is mandatory to prevent further progression to necrosis.[5] Our experience supports a phased approach, starting with edema reduction techniques, gradually shifting to more complicated approaches. However, for severe ongoing necrotizing damage as in Case 4, mechanical removal became impossible and total penectomy with the constricting device en bloc removal was done.

The most severe case in this series goes beyond penile entrapment into the category of rectal foreign body with urological complications. Rectal foreign body penetration into adjacent anatomical structures can present initially as an isolated colorectal pathology; however, delayed identification can result in pressure necrosis and erosion into adjacent organs. Enterovesical fistula can manifest as pneumaturia, fecaluria, or recurrent urinary tract infection. The rectal foreign body can result in erosion of the dome of bladder producing complex fistulous communication, as observed in our patients. The extensive surgery in the form of fistulous tract excision, urinary and fecal diversion, is sometimes required. Genitourinary foreign body leading to mortality is occasional but biologically plausible when sepsis occurs.[8] Similarly, our case-5 also represents a rare and severe presentation of rectal foreign body insertion progressing multiorgan fistulous communication and sepsis.

Psychiatric and behavioral assessment is crucial in understanding these presentations. Autoerotic motivation accounts for major lower urinary tract foreign bodies.[1] Nevertheless, the absence of officially reported mental illness does not preclude the compulsive and dangerous behavior. The drug abuse, impulses, and concealment due to guilty leads to delay in medical consultation[4,13] Oyibo *et al.* revealed that phallic ring insertion and behavioral or substance abuse factors are inter-related.[13] Thus, psychiatric consultation should be advocated into the standard treatment protocol.

This series does have limitations due to small sample size and absence of long-term follow-up, especially concerning erectile and psychological outcomes, which were recognized by Campbell *et al.*[6]

AHEAD OF PRINT..... AHEAD OF PRINT..... AHEAD OF PRINT..... AHEAD OF PRINT..... AHEAD OF PRINT..... AHEAD OF PRINT.....



Figure 1A- Convulated tube in urinary bladder on cystoscopy.

Figure 1B- Tube with multiple knots on open cystostomy

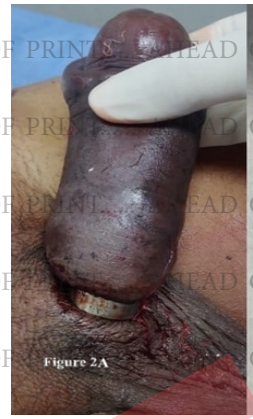



Figure 2A- Metallic ring at the base of penis.

Figure 2B- Metallic ring after removal.

Figure 3A- Rectangular shaped ring impacted at the coronal sulcus.

Figure 3B- Rectangular Ring after removal.

Figure 4A- Metallic ring at the base of penis., **Figure 4B-** Total penectomy specimen with ring as the base., **Figure 4C**- Metallic ring after removal.

AHEAD OF PRINT.....

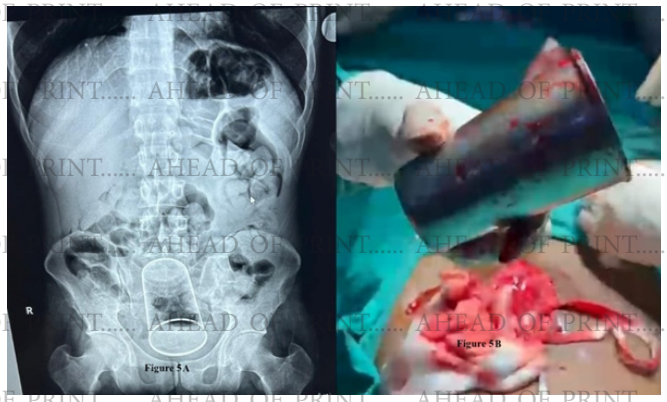

Figure 5A- Abdominal x-ray revealed an inverted glass object in the pelvis.

Figure 5B- A steel glass after removal.

CONCLUSION

Genitourinary foreign bodies comprise a wide range of the pathology, from intravesical foreign body, amenable to simple surgical extraction to time sensitive penile strangulation or even complicated rectovesical fistula with lethal outcomes. The most important in any management of this condition is timely diagnosis, appropriate severity assessment, and treatment, which must be tailored to every patient along with the holistic approach based on the psychological aspect.

REFERENCES

1. Moon SJ, Kim DH, Chung JH, Jo JK, Son YW, Choi HY et al. Unusual foreign bodies in the urinary bladder and urethra due to autoerotism. Int Neurourol J. 2010;14:186-9. DOI: 10.5213/inj.2010.14.3.186
2. Faridi MS, Mibang N, Rahman MJ, Singh RS. Giant bladder stone with foreign body and associated carcinoma urinary bladder. J Med Soc 2018;32:147-9. DOI: 10.4103/jms.jms_9_17
3. Mibang N, Faridi MS, Rahman MJ, Shantajit N, Lalrammuana R, Somarendra K. Glass ampoule in urinary bladder as a foreign body. Asian J Urol. 2016;3:96-98. DOI: 10.1016/j.ajur.2016.01.001
4. Khan MMA, Singh G, Kumar M, Goel A. Urethral sounding: Experience from two tertiary care centres in Northern India. J Clin Diagn Res. 2022;16:PC05-PC07. DOI: 10.7860/JCDR/2022/57881.16709
5. Dawood O, Tabibi S, Fiuk J, Patel N, El-Zawahry A. Penile ring entrapment – A true urologic emergency. Urol Ann. 2020;12:15-8. DOI: 10.4103/UA.UA_16_19.
6. Campbell KJ, Kwenda EP, Bozorgmehri S, Terry RS, Yeung LL. Penile strangulation: Analysis of postextrication follow-up, Sequelae, and a Review of Literature. Am J Mens Health. 2024;18(1): 5579883231223366. DOI: 10.1177/15579883231223366.
7. Bhat AL, Kumar A, Mathur SC, Gangwal KC. Penile stranguiation. Br J Urol. 1991;68(6):618–21. doi: 10.1111/j.1464-410x.1991.tb15426.x.
8. Easton-Carr R, Paish LM. Rectum Foreign Body Removal. [Updated 2025 Jul 7]. In: StatPearls [Internet]. Treasure Island (FL): StatPearls Publishing; 2025 Jan-. Available from: https://www.ncbi.nlm.nih.gov/books/NBK557557.
9. Pal DK, Bag AK. Intravesical wire as foreign body in urinary bladder. Int Braz J Urol. 2005;31(5):472-4. DOI: 10.1590/s1677-55382005000500010.
10. Agrawal M, Gite VA, Sankapal P. Two cases of penile strangulation. Afr J Urol. 2020;26:46. DOI: 10.1186/s12301-020-00057-2.
11. ouka SCN, Diallo Y, Niang L, Diop Ak, Sylla C. Gangrene of the penis due to strangulation by metallic ring. Andrology. 2014;3:1000121. DOI:10.4172/2167-0250.1000121
12. Paonam S, Kshetrimayum N, Rana I. Penile strangulation by iron metal ring. Urol Ann. 2017;9(1):74-6. DOI:10.4103/0974-7796.198873.
13. Oyibo UE, Iyabor NO, Akhaine JO, Onwukwe JC. Phallic ring entrapment and strangulation. Int Surg J. 2023;10:139-42. DOI:10.18203/2349-2902.isj20223606
14. Vyas KN, Solanki MI. Penile strangulation by a metal ring: an easy and unique thread method for removal of the ring. Int Surg J. 2019: 6(2):623–6. DOI:10.18203/2349-2902.isj20190418.

Orcid ID:
Mohammad Shazib Faridi - https://orcid.org/0000-0002-9305-3704
Abdul Qadir Boringwala - https://orcid.org/0009-0007-8855-6570
Kartik Sridhar - https://orcid.org/0000-0002-6455-231X
Devesh Bhatia - https://orcid.org/0009-0002-7810-6422
Neel Swaminarayan - https://orcid.org/0009-0007-6741-2842
Prashant Garg - https://orcid.org/0009-0009-0928-0786